



سوره حمد





“تزریق بوتاکس اطراف چشم و صورت”

دارای ۲ امتیاز
آموزش مداوم

برگزار کننده:

انجمن چشم پزشکی خراسان

با همکاری:

انجمن چشم پزشکی ایران و

گروه چشم دانشگاه علوم پزشکی مشهد

پنجشنبه ۲ تیرماه ۱۴۰۱ - ساعت ۲۰ الی ۲۲
آدرس لینک وینار در اپلیکیشن زوم :

<https://zoom.us/j/89097831298?pwd=ZkZnaoFiOTQrNmFuajdsRVROSVdiZz09Meeting>
ID: 890 9783 1298
Passcode: IRSO

Panelists:

Coordinator:



Mortazavi Fard
M,MD



Abrishami M,MD



Bahmani Kashkouli
M,MD



Karimi N,MD



Khademi B,MD



Jafarpoor S,MD

Moderator :



Etezad Razavi M,MD

Speaker :



Shekarchian F,MD

The Aging Face: A New Paradigm

- Views the face in 3 dimensions
- Recognizes the importance of volume loss and facial deflation
- Strives to restore volume and create the smooth facial curves of youth

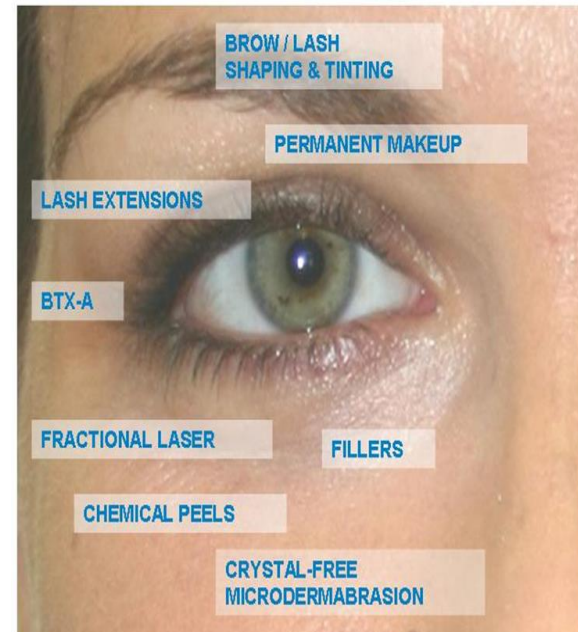


How Has This New Paradigm Changed Practice?

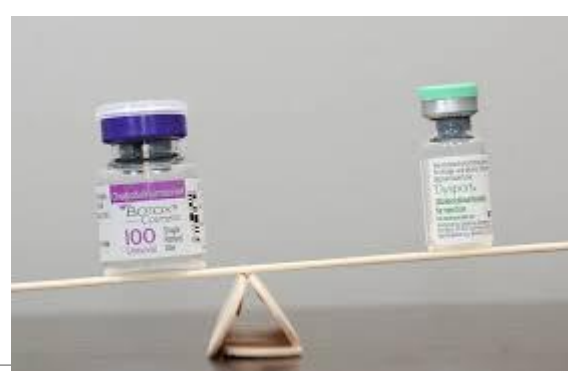- Practice management: Minimally invasive procedures keep patients coming back to the practice
- Treatment philosophy: A more natural look

“Less is more”

Think Outside the Box but Inside the Frame



Botulinum Toxin



Farid Shekarchian.MD
MUMS


Historical background



Clostridium botulinum was **first identified in 1897**, in Belgium, by **Professor Emile** van Ermengem who was investigating fatal cases of food poisoning following the consumption of macerated ham.

It was named after the disease it causes, botulism, a lethal form of food **poisoning originally associated with sausage meat** (botulus is Latin for sausage).

There are seven known **serotypes** of botulinum toxin (**A, B,C,D, E, F, and G**).



Dr Alan Scott (an ophthalmologist from the Smith-Kettlewell Eye Research Foundation), became interested in substances that caused transient muscular paralysis.

He acquired botulinum toxin Type A from Fort Detrick, and performed the **first clinical tests on humans in 1978.**

His results in the *treatment of strabismus* were published in 1980

Botulinum Toxin: Mode of action

Botulinum **neurotoxins are polypeptides.**

Botulinum toxin comprises a protein molecule (150kd) which can be cleaved into a **heavy (H)(100kd) and a light (L)(50kd) chain** .

These chains are normally held together by a **disulphide bond**, which is heat labile.

Disruption of this bond inactivates the neurotoxin.

This explains why botulinum toxin **must be stored at the correct temperature and reconstituted carefully**, preserving the integrity of the two chained molecule.

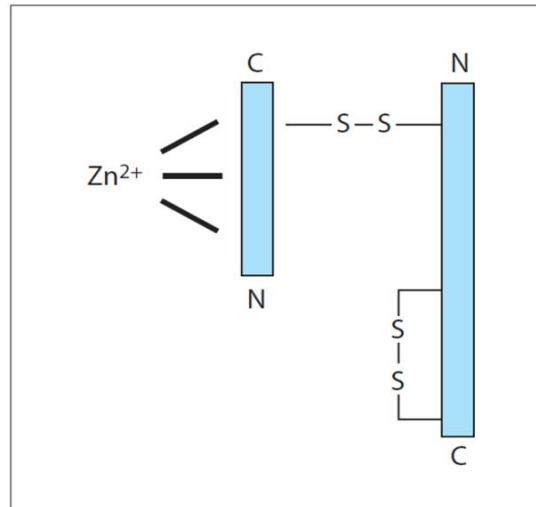
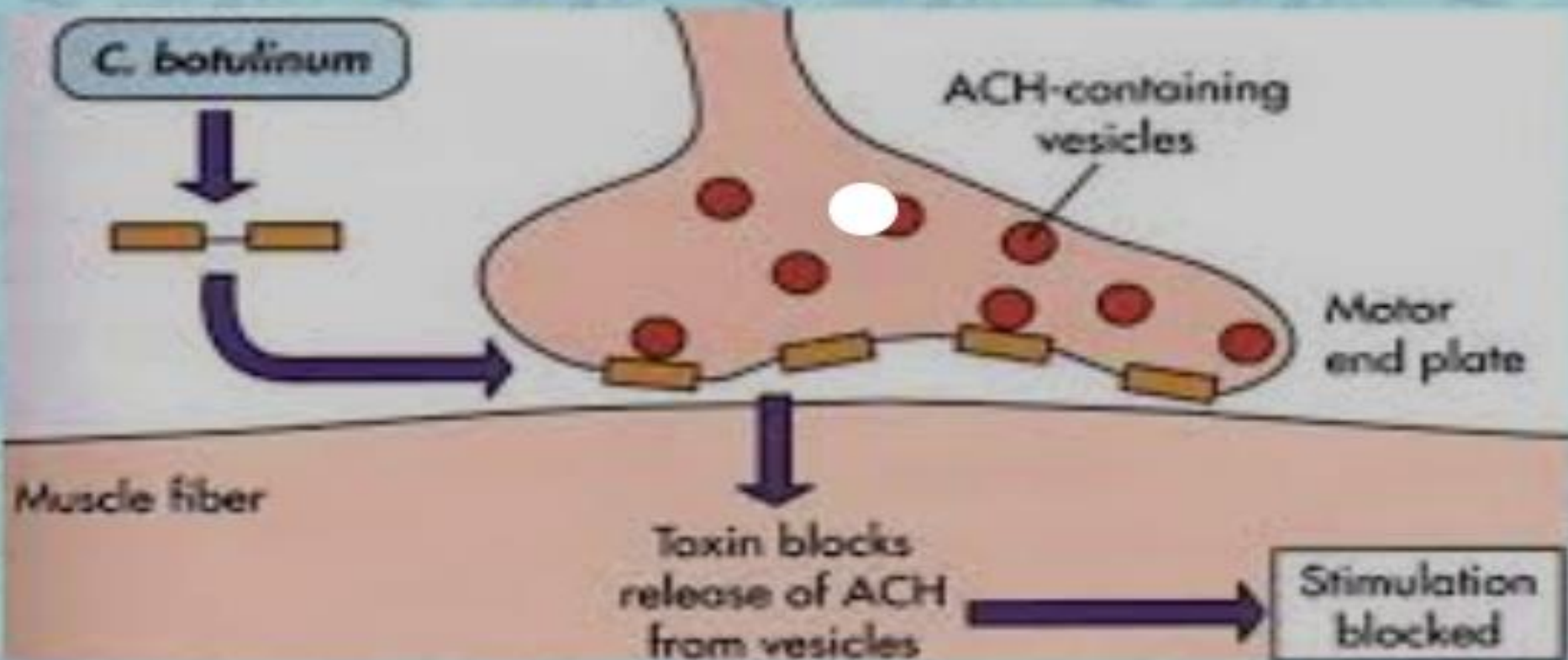


Fig 2.1 Diagram of botulinum toxin molecule showing heavy and light chains. After Aoki, R. The development of botox – its history and pharmacology. Pain Digest 1998;8:337–341 by permission of Springer-Verlag.

Botulinum toxin induces paralysis by **blocking the release of acetylcholine at the skeletal neuromuscular junction**, thereby inhibiting the transmission of nerve impulses across the synaptic junction to the motor end plate.

Mechanism of Action of Botulinum Toxin



Comparison of botulinum neurotoxin products marketed in Europe and North America


Units are manufacturer specific and are not interchangeable.

	Botox/Vistabel	Dysport/Azzalure	Xeomin/Bocouture	Neurobloc/Myobloc
Generic name	OnabotulinumtoxinA	AbobotulinumtoxinA	IncobotulinumtoxinA	RimabotulinumtoxinB
Manufacturer	Allergan (USA)	Ipsen Pharmaceuticals (France)	Merz Pharmaceuticals (Germany)	US WorldMeds (USA)
<i>C. botulinum</i> strain	Hall A-hyper	Hall A	Hall A (ATCC 3502)	Bean
Toxin type	A1	A1	A1	B1
MW (PTCs)	900 kDa complex (Yes)	MW not reported (Yes)	150 kDa None	MW not reported (Yes)
Pharmaceutical form	Vacuum-dried powder for reconstitution	Freeze-dried powder for reconstitution	Freeze-dried powder for reconstitution	Ready-to-use solution
Shelf life	2–8°C 36 months	2–8°C 24 months	Room temperature 36 months	2–8°C 24 months
pH (reconstituted)	7.4	7.4	7.4	5.6
Excipients	In 100 U vial: HSA 500 µg NaCl (900 µg/vial)	In 500 U vial: HSA 125 µg Lactose (2.5 mg/vial)	In 100 U vial: HSA 1000 µg Sucrose (4.7 mg/vial)	HSA 500 µg/ml Succinate 10 mM NaCl 100 mM
Unit/vial	100 U or 200 U Botox 50 U Vistabel	300 U or 500 U Dysport 125 U Azzalure	100 U or 200 U Xeomin 50 U Bocouture	2500 U/0.5 ml 5000 U/1 ml 10,000 U/2 ml
Protein load/vial	5 ng/100 U	4.35 ng/500 U	0.44 ng/100 U ^a	55 ng/2500 U
Clinical activity in relation to Botox	1	1:2–1:3	1	1:40–1:50

HSA, human serum albumin; PTC, progenitor toxin complex.

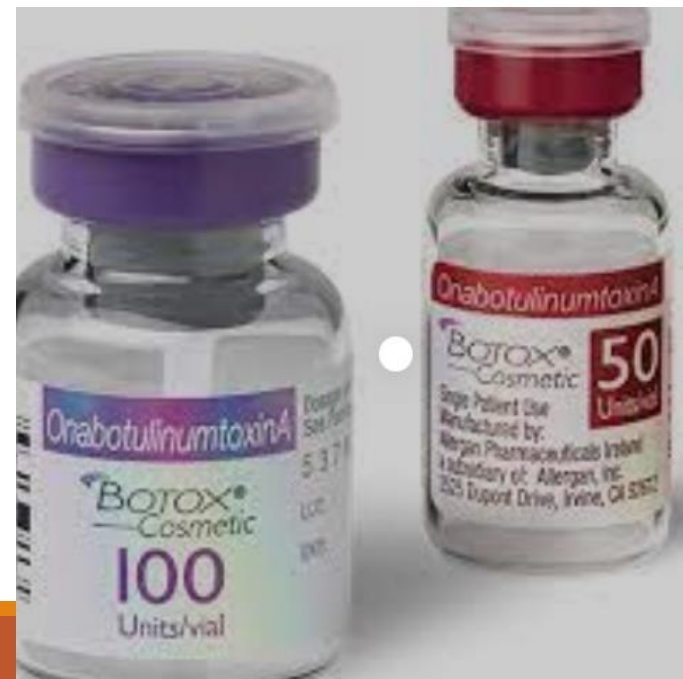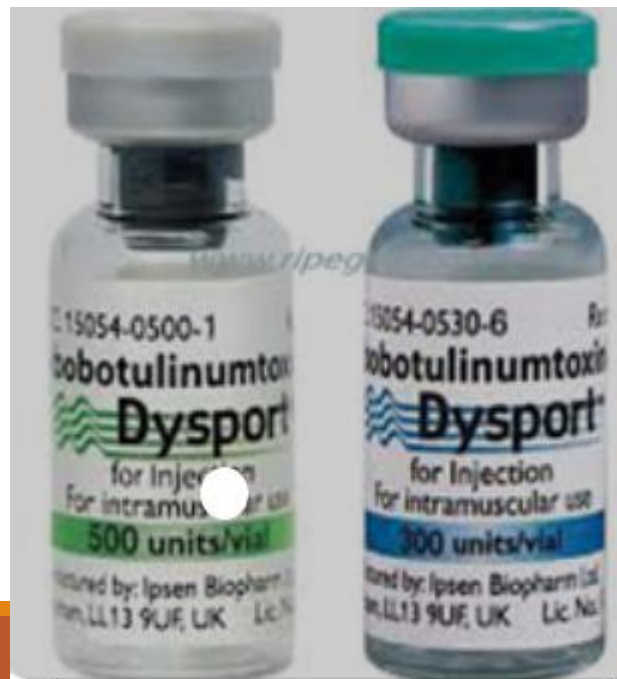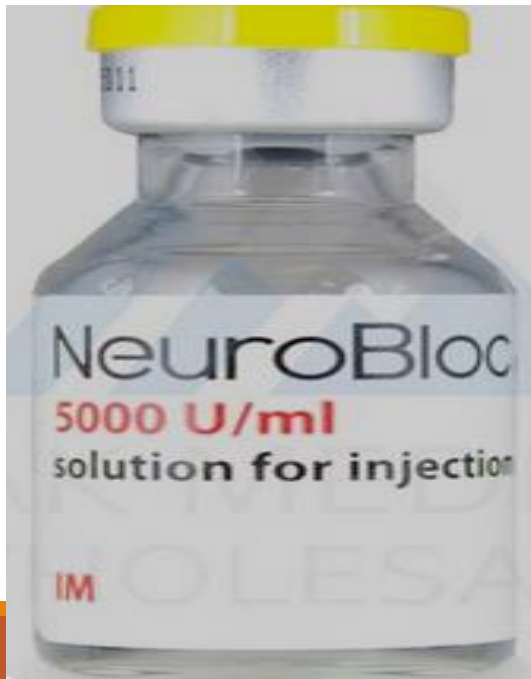^aNeurotoxin concentration measured by ELISA (Frevort, 2010).

Table 4.1. A comparison of the different commercially available botulinum toxins

	Botox®	Dysport®	NeuroBloc®
Presentation	Single 100 unit vial (frozen)	Two 500 unit vials (refrigerated)	0.5 ml, 1.0 ml or 2.0 ml vials (refrigerated)
Form	Freeze dried powder	Freeze dried powder	Liquid protein complex
Reconstitution	0.9% preservative free saline	0.9% preservative-free saline	May be further diluted with 0.9% preservative-free saline
Recommended storage before reconstitution	One year frozen at $\leq 5^{\circ}$ or one year refrigerated at $2-8^{\circ}$	One year refrigerated at $2-8^{\circ}$	18 months under refrigeration at $2-8^{\circ}$ or 8 hours at room temperature
			
Recommended storage after reconstitution	Four hours at $2-8^{\circ}$ Should not be frozen	Eight hours at $2-8^{\circ}$ Should not be frozen	If diluted, no more than 8 hours at either room temperature or under refrigeration

Three types of botulinum toxin are currently available commercially: Botox[®] and Dysport[®] (both botulinum toxin Type A); and NeuroBloc[®] (botulinum toxin Type B).

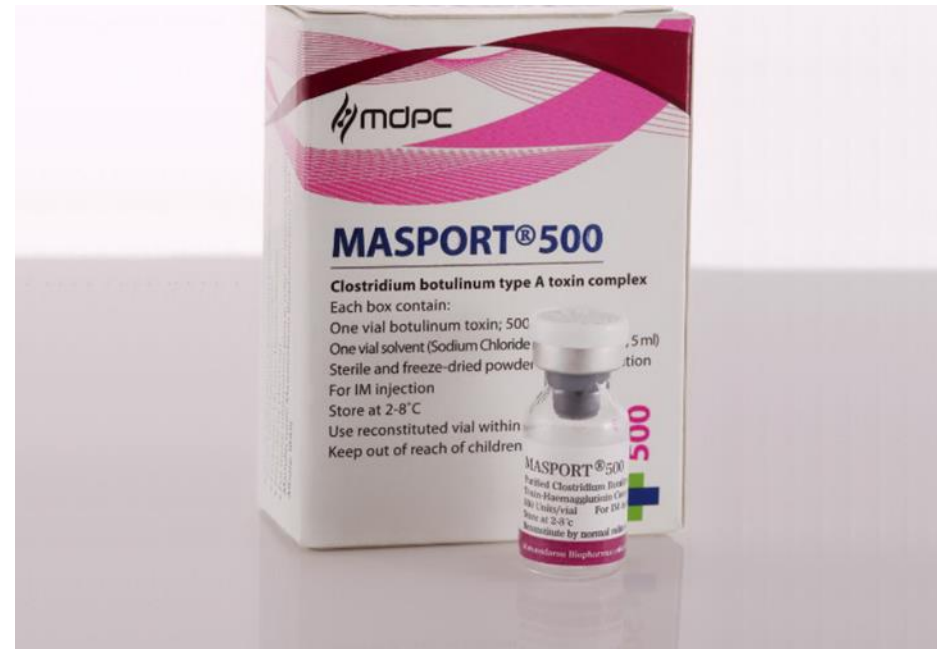Allergan in Westport, Ireland produces Botox[®]. Dysport[®] is produced by Ipsen Pharmaceuticals, UK, and NeuroBloc[®] is produced by Elan, Ireland.





ديستون 500 واحدی

- بوتولينوم توکسين نوع A
- پودر لئوفيليزه تزريقي است.
- در هر جعبه ديستون : یک ويال ديستون 500 + حلال سدیم کلراید 0.9% + بروشور
- شرایط نگهداری : 2-8 درجه سانتی گراد

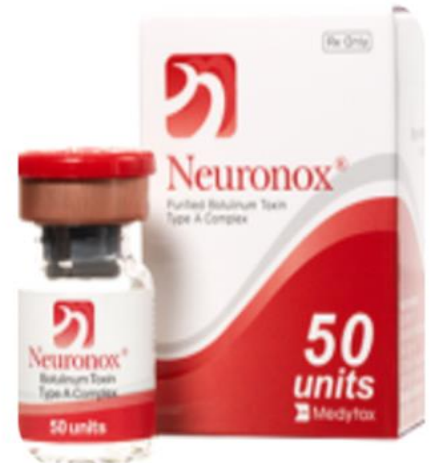

Neuronox[®]

The First Choice of Botulinum Toxin Type A



Well proven
efficacy and safety



Botox[®] units are **not equivalent to** Dysport[®] units

One Botox[®] unit is **3-5 times stronger** than one Dysport[®] unit.

One Botox[®] vial has 100 units but one Dyport vial has 500 units.

Low concentrations diffuse further than high concentrations.

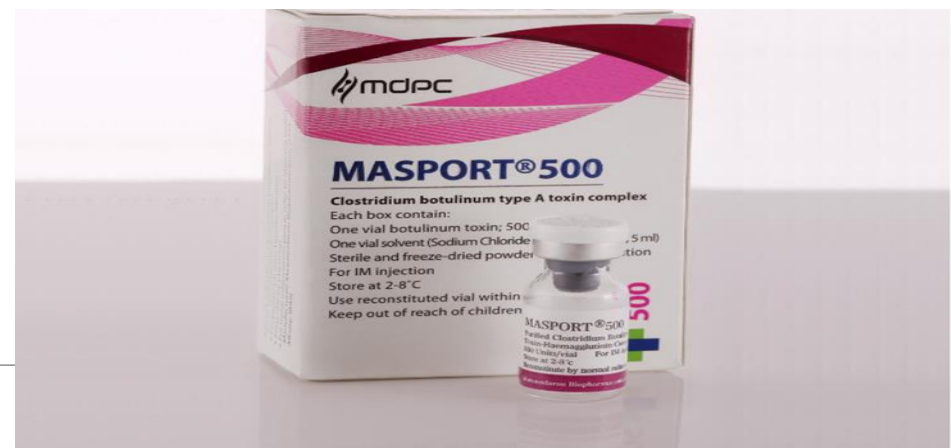High concentrations last 12 weeks, low concentrations often wear off sooner

Preparation, storage and injection technique

- ❑ Once **reconstituted**, Botox[®] must be **stored at 2–8°** centigrade (refrigeration temperature).
- ❑ **Dysport[®]** does not have to be stored in a deep freeze but, once **reconstituted**, it must be kept **at 2–8° centigrade**. Ipsen recommend **using it within eight hours of reconstitution**
- ❑ **NeuroBloc[®]** is a liquid and **If diluted with saline, it should not be stored for longer than 8 hours**

-
- ❑ Never agitate botulinum toxin solution when reconstituting it.
 - ❑ Remember that, on average, 4 units in 0.1 ml of Botox[®] will diffuse 1 cm; **20 units of Dysport[®] in 0.1 ml will diffuse 1.5 cm;**
 - ❑ *20 units of Dysport[®] in 0.05 ml will diffuse less far; as will 2 units of Botox[®] in 0.05 ml.*

MASPORT



Reconstitute by free preservative **3.2 ml sterile sodium chloride 0.9%** that **every 0.1 ml has 15.6 unit** of toxin

Glabellar lines total dose **50 units** into 5 sites

Forehead lines (**frontalis**) total dose **40 units**

Crow's feet lines total dose **10 unit**

Concentration of botulinum toxin:

Too weak = short duration of action

Too strong = risk of increased side effects

USER TIP



Increased volume dilution per unit botulinum toxin means increased diffusion.

Increased Diffusion

GOOD FOR:

- Treatment of frontalis
- Extended treatment of crow's feet (inferolaterally over zygomatic arch)

Reduced Diffusion

GOOD FOR:

- Lateral canthus
- Pre tarsal orbicularis
- Close to superior orbital rim

Table 5.3 Recommended Dysport[®] dosage for upper face.

Indications	Total usual dose (Dysport [®] units)	Dose range (Dysport [®] units)
Glabella	50	30–70
Forehead	40–50	40–70
Crows' feet	30 × 2	20–50 × 2
Lateral eyebrow lift	20 × 2	20–40 × 2
Glabella & forehead	90–100	70–140
Glabella & lateral eyebrow lift	90	50–110
Complete upper third face	150	110–240

Patient Preparation Checklist

Blood-thinning products and dietary supplements should be discontinued for 10 to 14 days before injection to minimize bruising.

All areas to be treated should be free of makeup and lipstick.

Topical anesthesia can be used in the form of cold compresses applied to the intended injection sites and a eutectic mixture of local anesthetics, if desired.

Injections may be given with the patient in either the upright or supine position.

INJECTION TECHNIQUE

An inexperienced worker should **mark the injection sites** with a washable skin marker, having **first wiped the sites with an alcohol** swab.

It is important to sterilize the skin at the injection site, as many patients wear a **make-up foundation**.

Local granulomas or erythematous nodules can develop at injection sites

Botulinum toxin can be injected **intramuscularly or subcutaneously**

Subcutaneous injections are also effective but need more injection sites to allow for maximum absorption

Intramuscular placement **stings less**, and produces **less local erythema**. However it carries a slight risk of causing intramuscular **bruising**.

Spread the skin between two fingers to observe the **orbital veins** clearly and take care to inject around these.

Slow insertion of the needle can greatly **reduce the perception of pain**, possibly by minimizing the mechanical stimulation of cutaneous pain receptors.

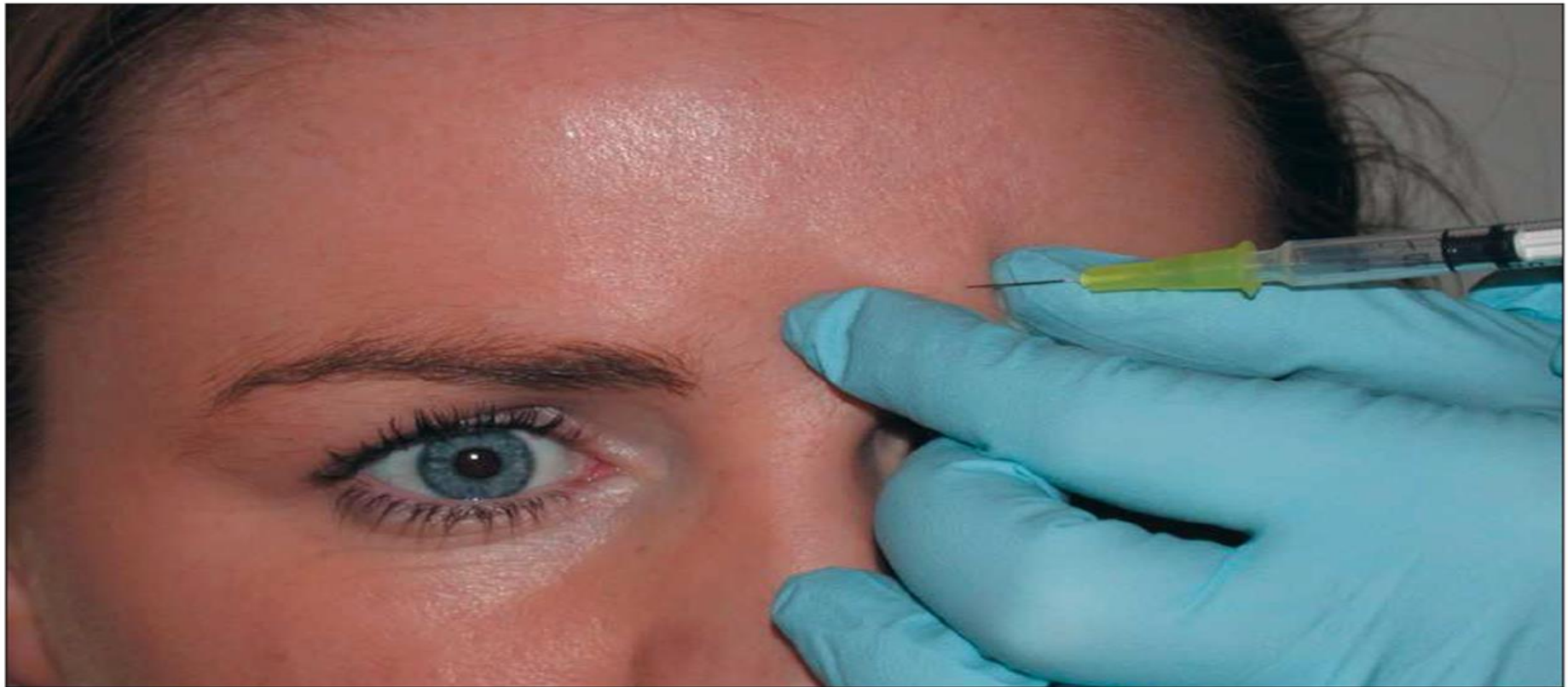

Fig 4.7 Holding the muscle between two fingers when injecting the glabella.

POST-INJECTION

Any bruising that occurs should be treated immediately with an ice pack from the freezer.

Cosmetic Facial Botulinum Toxin Injections

Frontalis Muscle

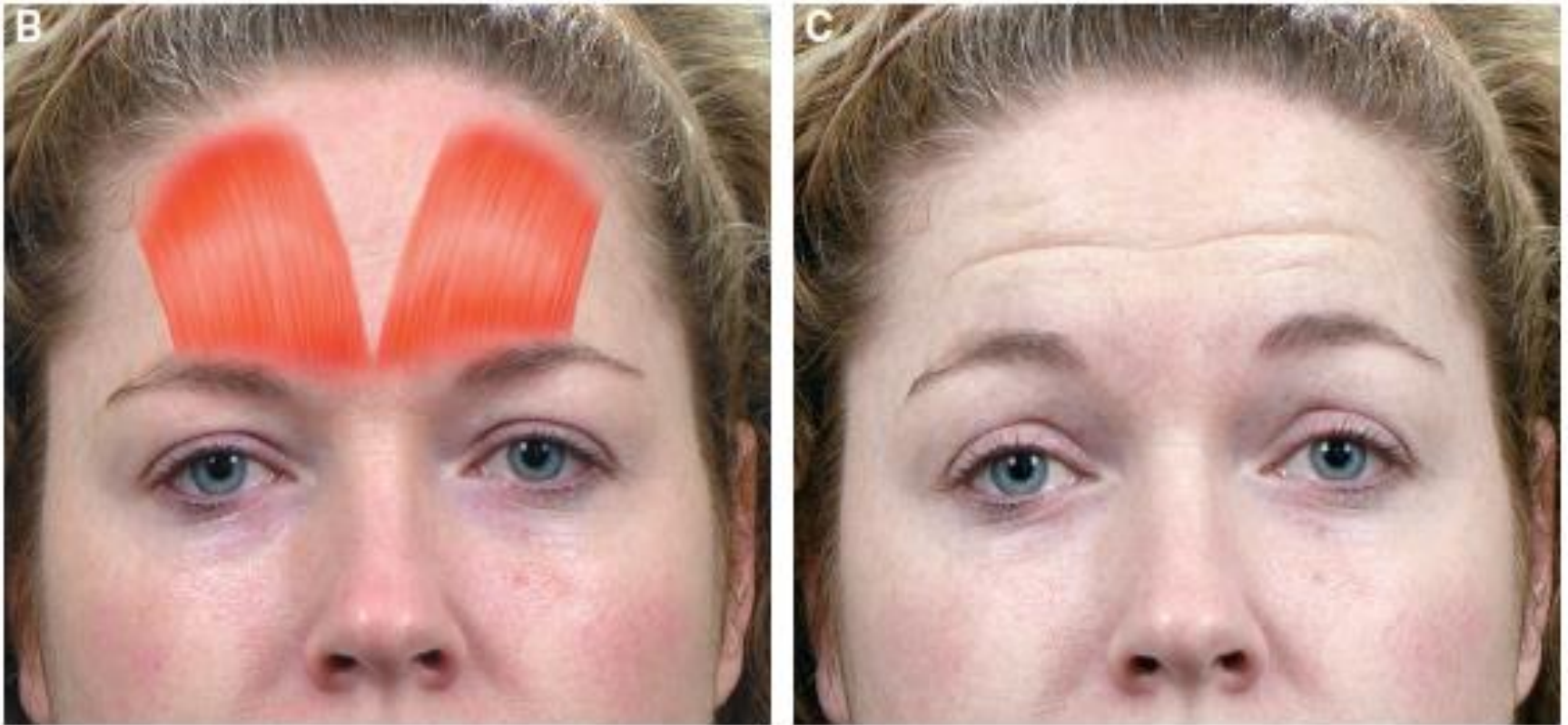

Fig. 20-2 A, Anatomy of the frontalis muscle. B, Overlay of the frontalis muscle. C, Action of the frontalis muscle, which causes transverse forehead lines.

Cosmetic Facial Botulinum Toxin Injections

Frontalis Muscle

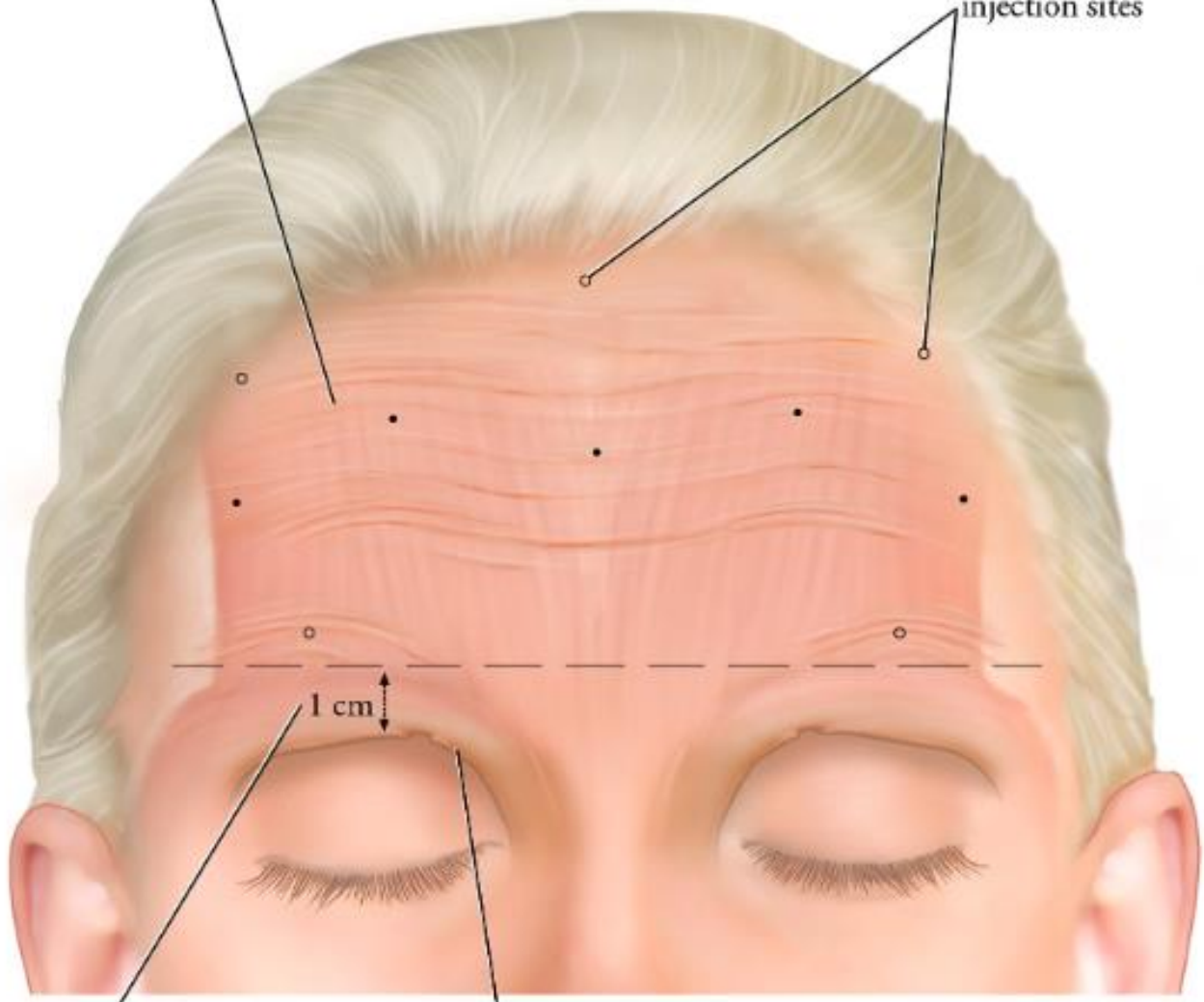
Typical injection doses for the frontalis muscle are **1.25 to 2 units of botox (5-10 U of Dysport or Masport)** per each of 6 to 10 injection sites, depending on the size of the patient's forehead and the muscle bulk.

The injection level is in the **deep subcutaneous plane**, immediately superficial to the muscle. **Inferior injections should be placed 1 to 2 cm above the brow** to avoid secondary brow ptosis.

Paralysis of the entire frontalis muscle without compensatory paralysis of the brow depressors (the procerus, corrugator supercilii, and depressor supercilii muscles) should not be performed, because this may **result in profound brow ptosis**.

Frontalis m.

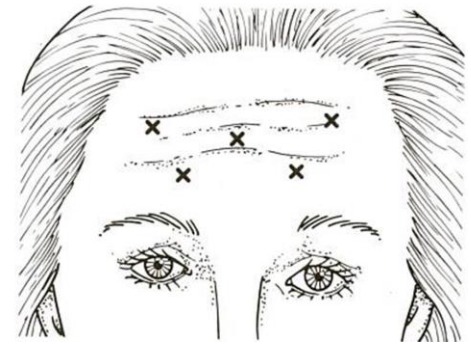
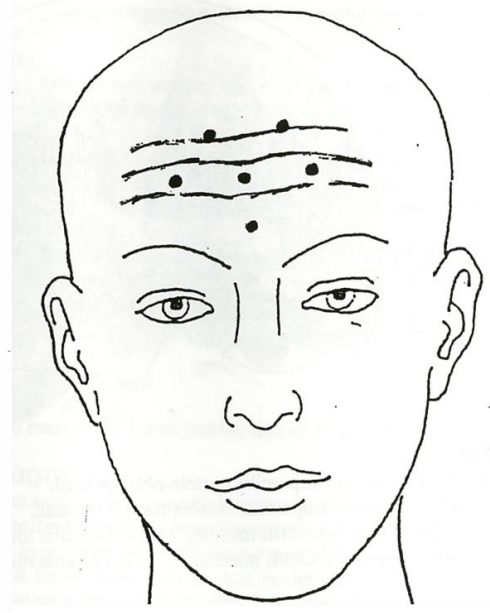
Optional injection sites



b

Do not inject within 1 cm of supraorbital rim

Supraorbital rim

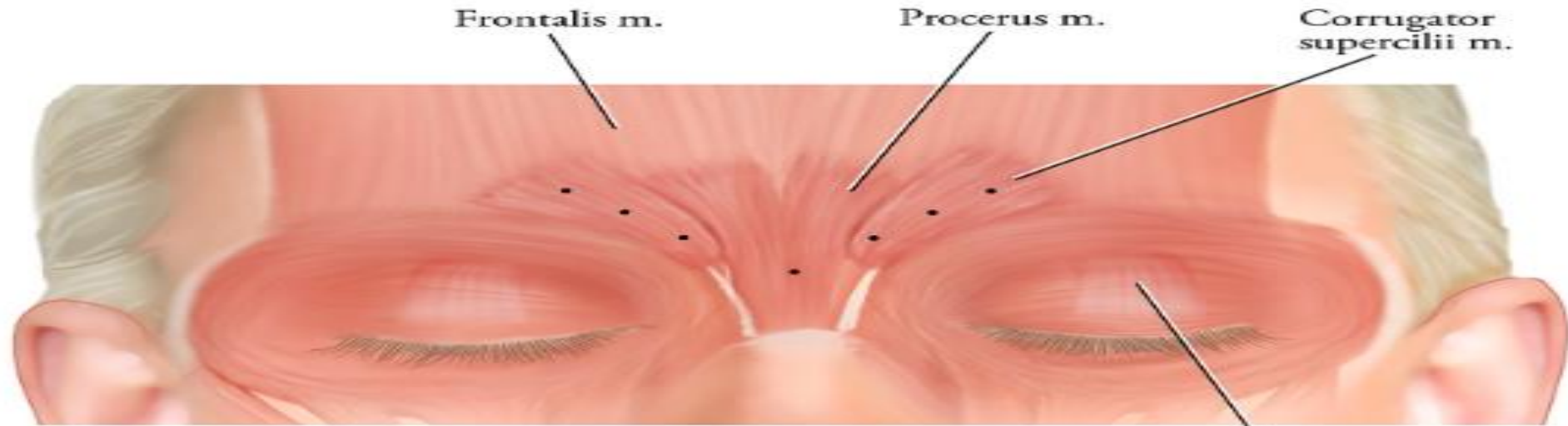


Horizontal forehead wrinkles
2 to 3 units BTX per/site
or 6 to 9 units disport per/site

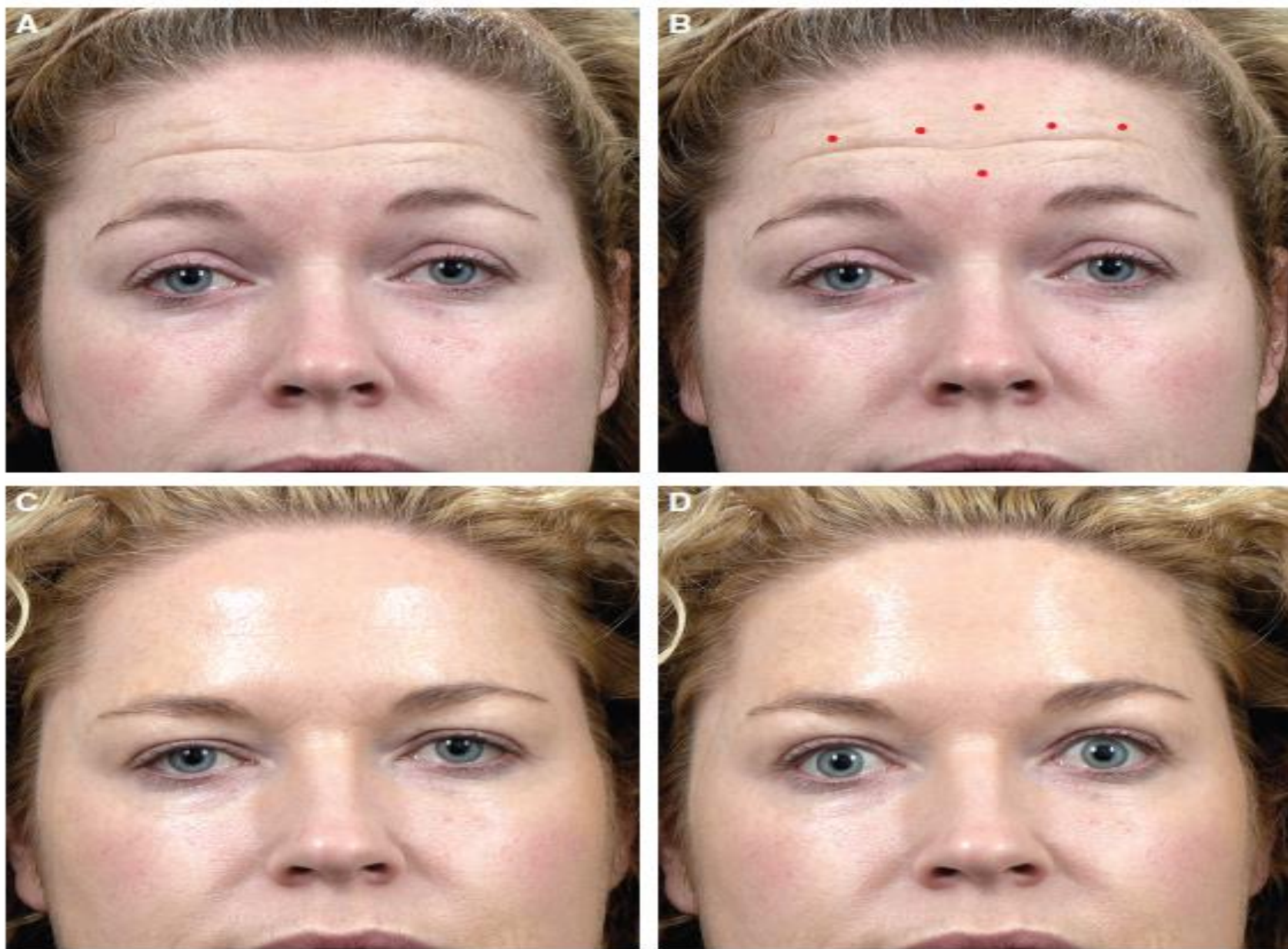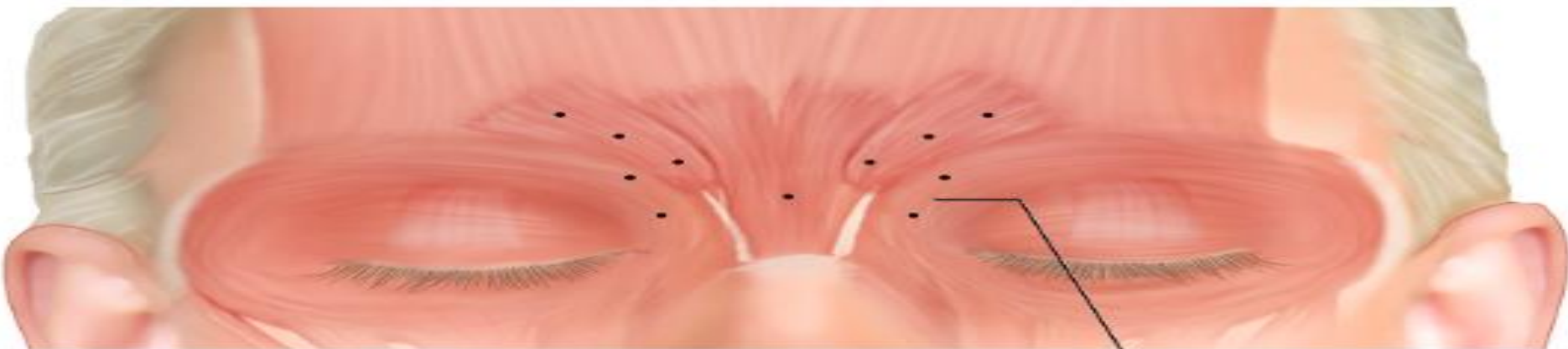


Fig. 20-7 **A**, This patient complained of transverse forehead lines. **B**, The locations of the injection sites for the treatment of transverse forehead lines are shown. **C**, The patient is shown 3 weeks after injection, with smoothing of the forehead at rest. **D**, The postinjection effect on the frontalis muscle during attempted brow elevation is shown.

Procerus Muscle and Corrugator Supercilii Muscle



Levator palpebrae superioris m.



Injections to medial orbicularis oculi m.

If the frown is dynamic only in motion, the result of treatment may well be a good one.

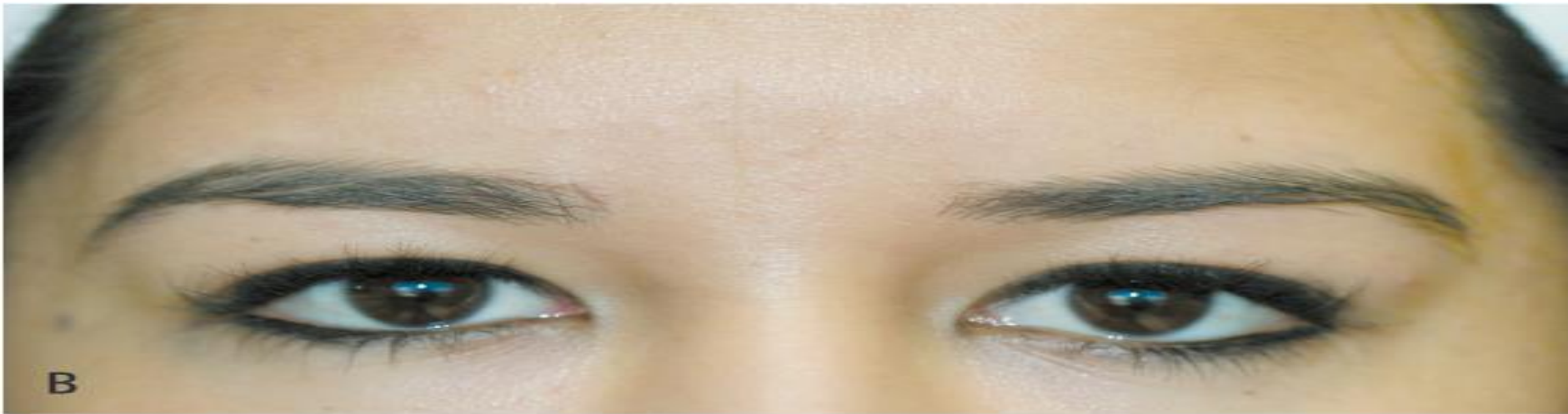
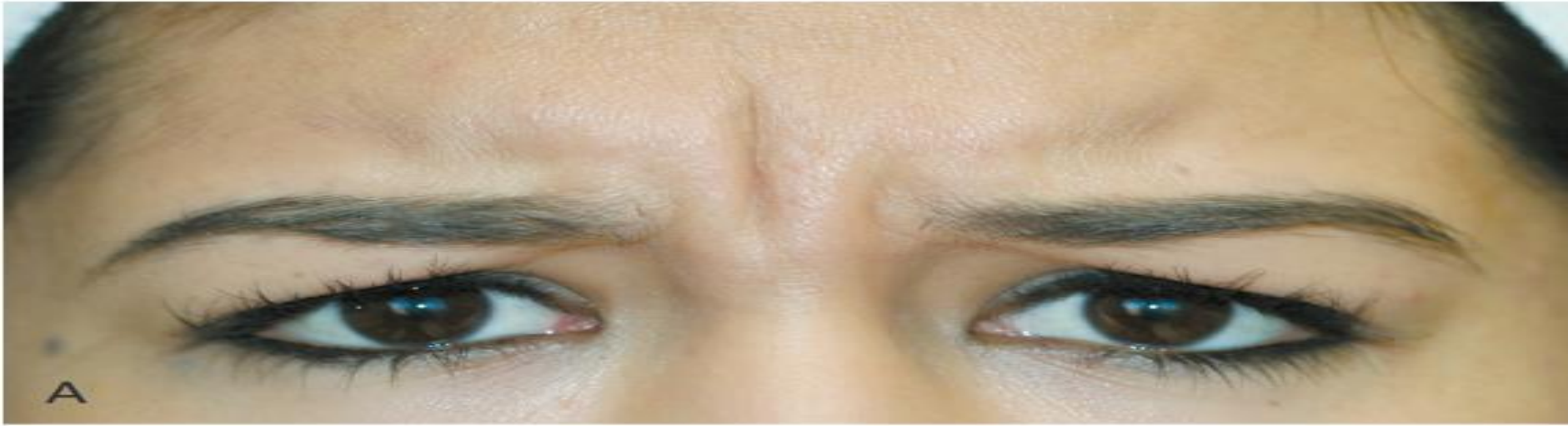
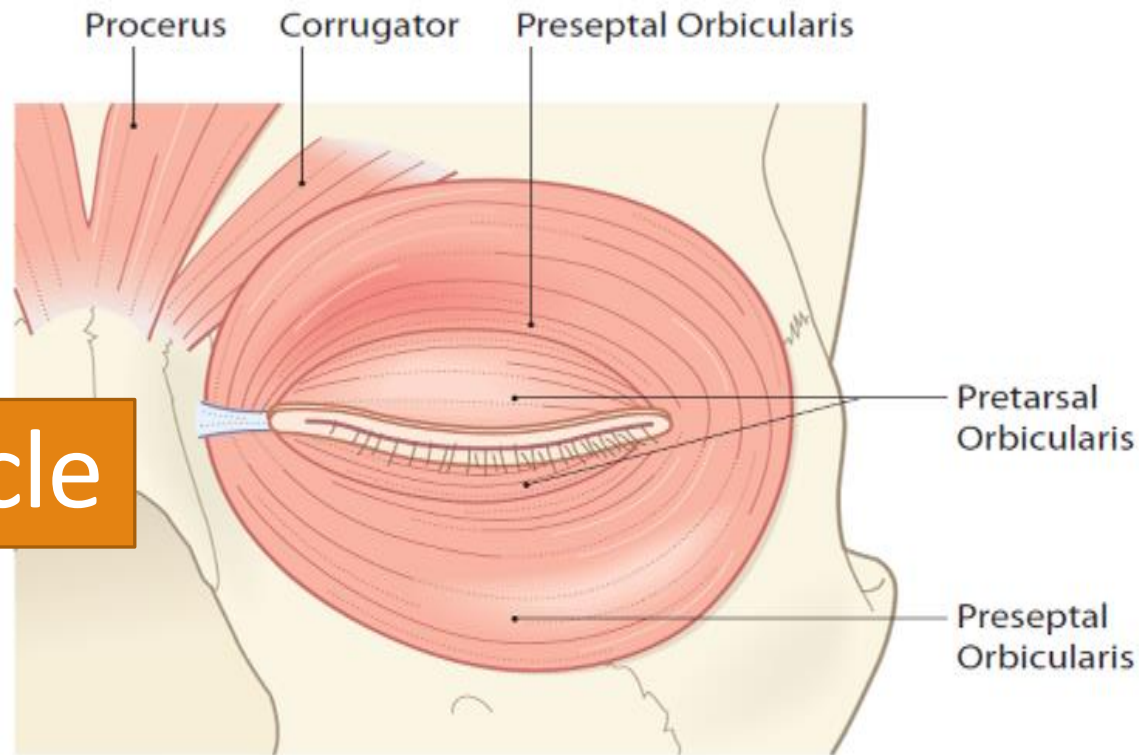
Figure 4. Ideal candidate for botulinum toxin treatment demonstrating (A) dynamic frown lines with glabellar complex muscle contraction and (B) lack of static lines with glabellar muscles at rest.

If the furrow is present at rest: warn the patient that it may not be completely eliminated

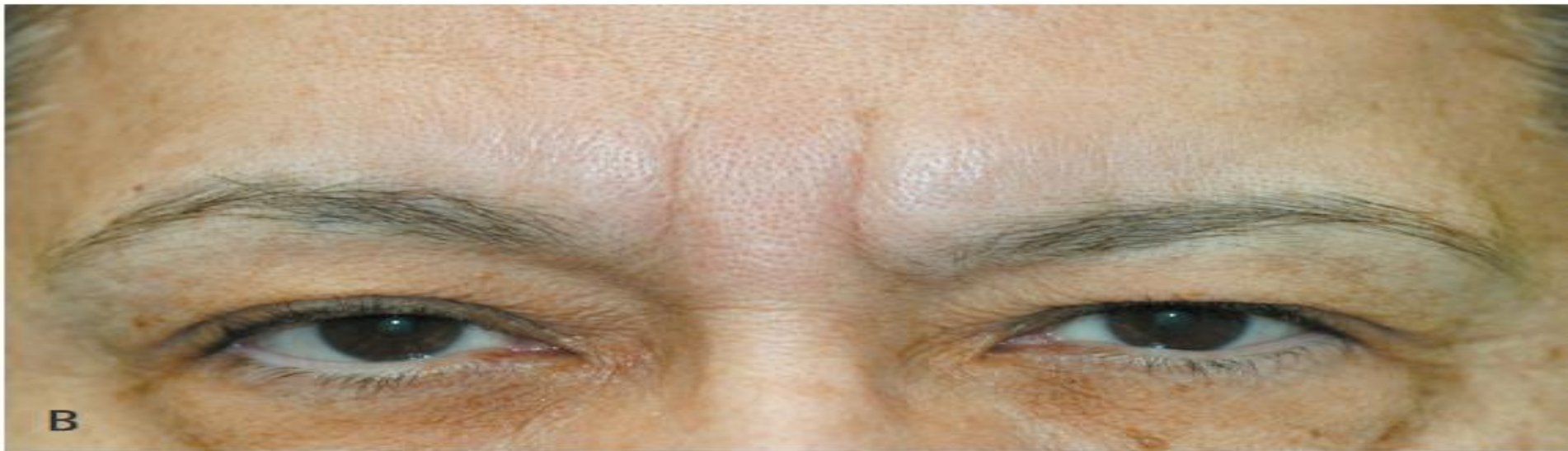
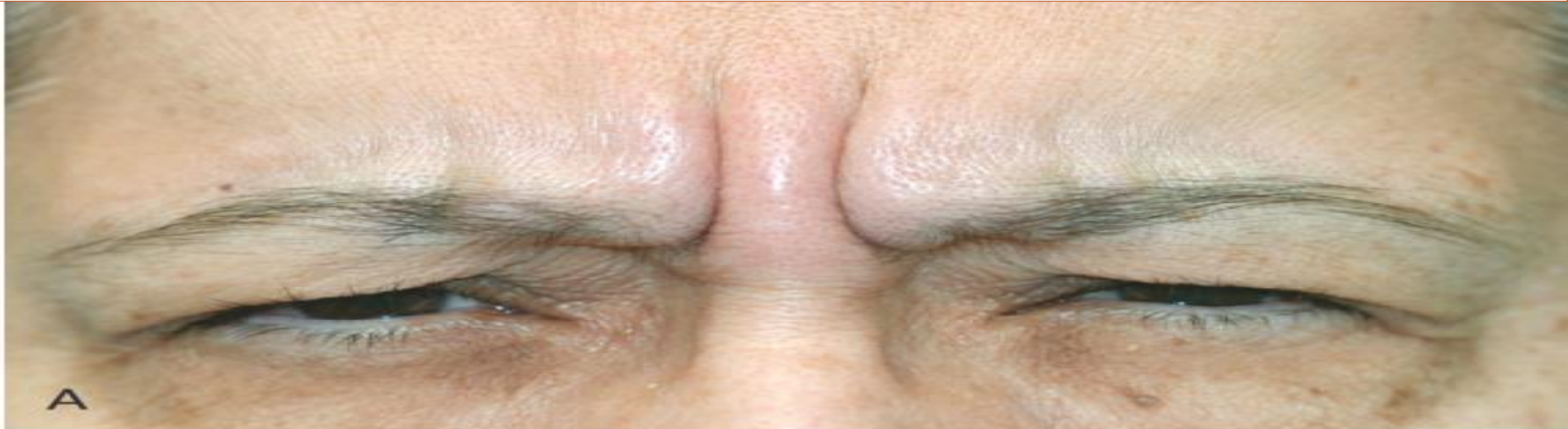
Figure 5. (A) Dynamic frown lines with glabellar complex muscle contraction and (B) static lines with glabellar muscles at rest.

Procerus Muscle



Care must be taken to **avoid the supratrochlear neurovascular bundle when injecting** the procerus muscle.

A single **midline injection of 4 to 5 units** of neurotoxin placed **subdermally or intramuscularly 0.5 cm above the upper eyebrow border** is adequate to treat horizontal glabellar lines.

Periosteal injections should be avoided because they are usually painful and unnecessary

Corrugator Supercilii Muscle

Each corrugator muscle is usually **injected twice, medially and laterally**, so that both the oblique and transverse heads are treated. Each injection should include **4 to 5 units** of neurotoxin

The **medial injection** should be **1 cm from the midline and 1 cm superior to the brow** to avoid the **supratrochlear neurovascular bundle**, which is **1.5 cm from the midline**.

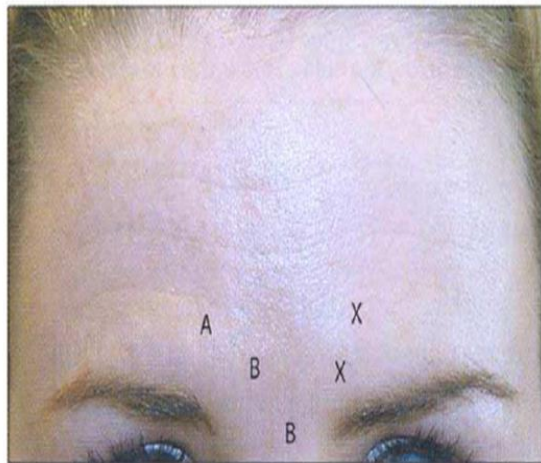
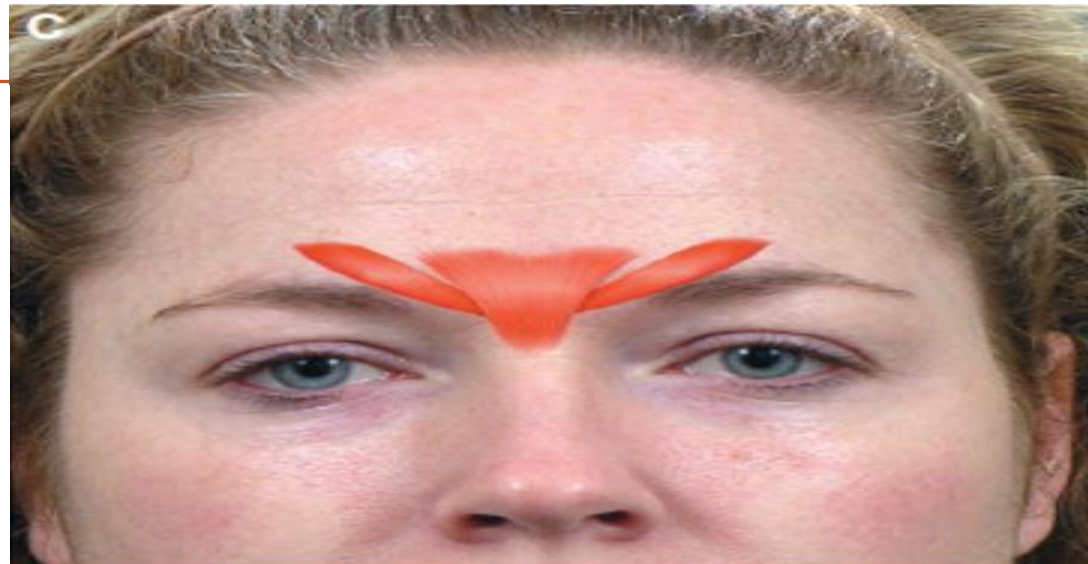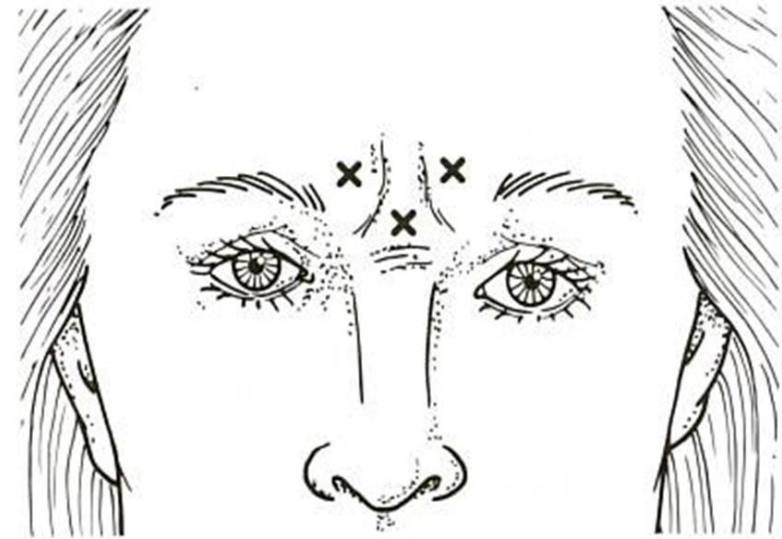

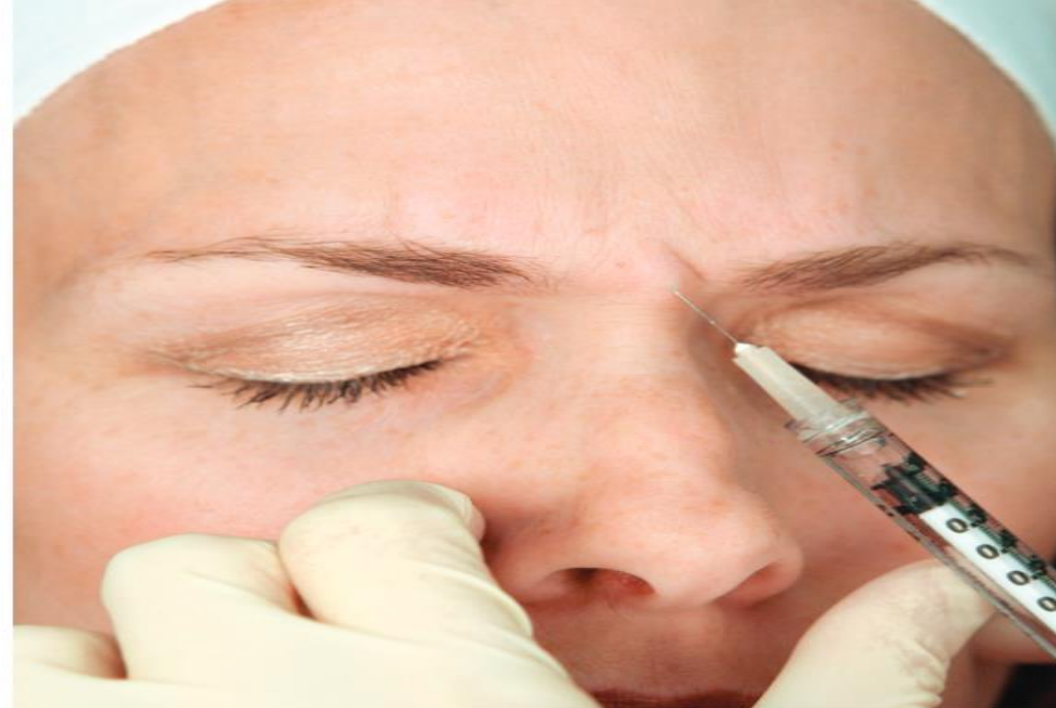
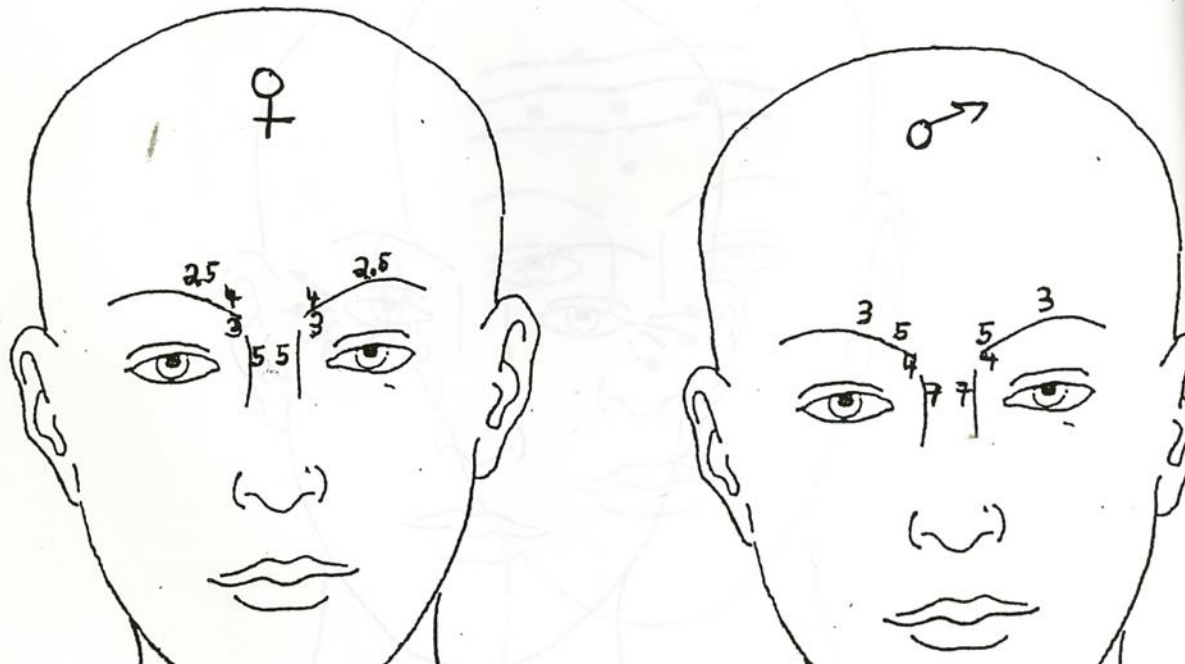
Fig 8.16 Suggestion for glabellar treatment in inexperienced hands. A, 0.1 ml; B, 0.05 ml.





Glabellar folds

5 to 10 units BTX per/site
15 to 30 units dysport per/site



GLABELLA

Remain 1 cm outside of bony orbital margin, especially superiorly
Men require larger doses because have larger muscle mass

Arched brows require no lateral injections and smaller doses (small depressors)

Procerus:	5 units (females)	7 units (males)
Medial Corrugator:	4 units (females)	5 units (males)
Orbicularis Oculi:	3 units (females)	4 units (males)

Horizontal brows require lateral injections and larger doses (larger depressors)

Procerus:	5 units (females)	7 units (males)
Medial Corrugator:	4 units (females)	5 units (males)
Lateral Corrugator:	2.5 units (females)	3 units (males)
Orbicularis Oculi:	3 units (females)	4 units (males)

Complications:

- Diplopia—if too close to orbit margin, treat with Fresnel prism
- Lid Ptosis—“ “ “ “ “, treat with Iopidine (Alcon)
- Headache—will resolve

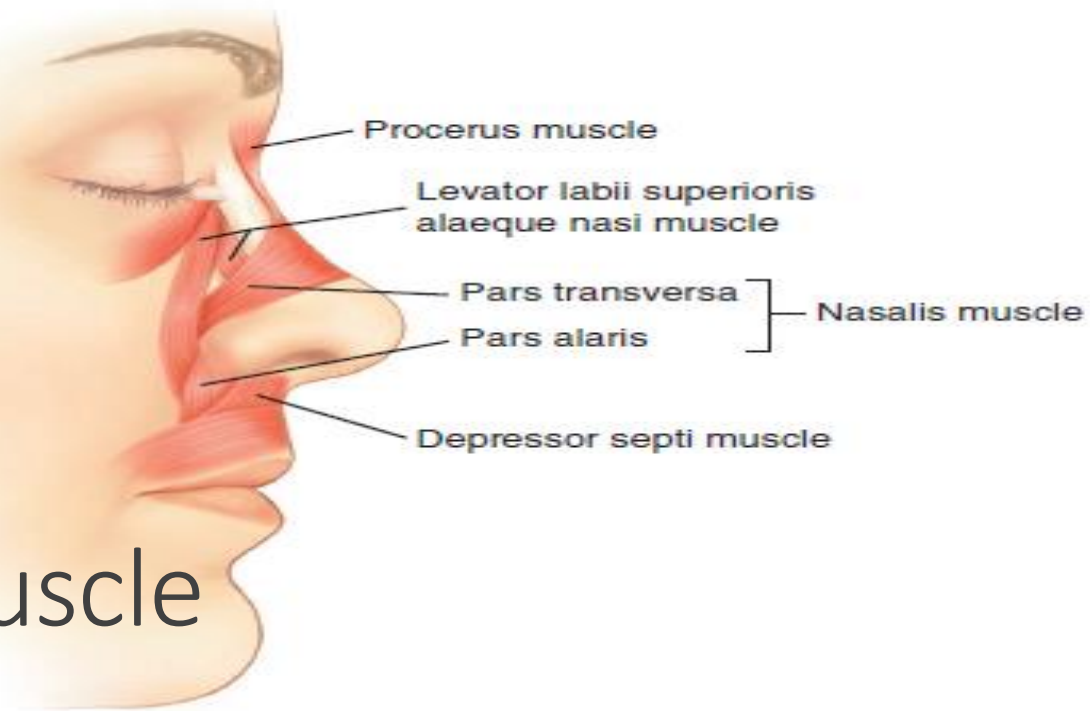
Adjunctive Procedures:

- Upper Lid Blepharoplasty
- Brow/Forehead Lift (endoscopic, coronal, pretrichial, trans-lid)
- Soft tissue augmentation (injectables, grafts) for contour defects

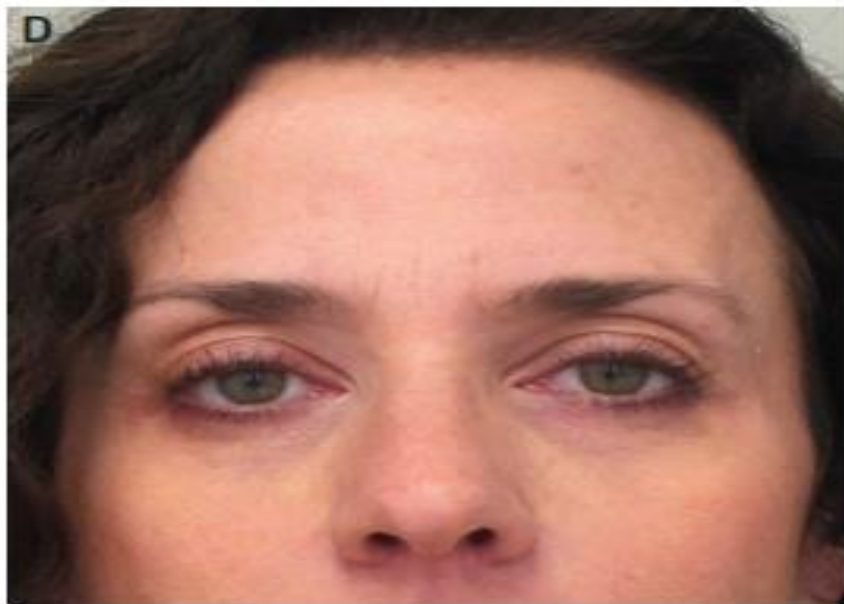
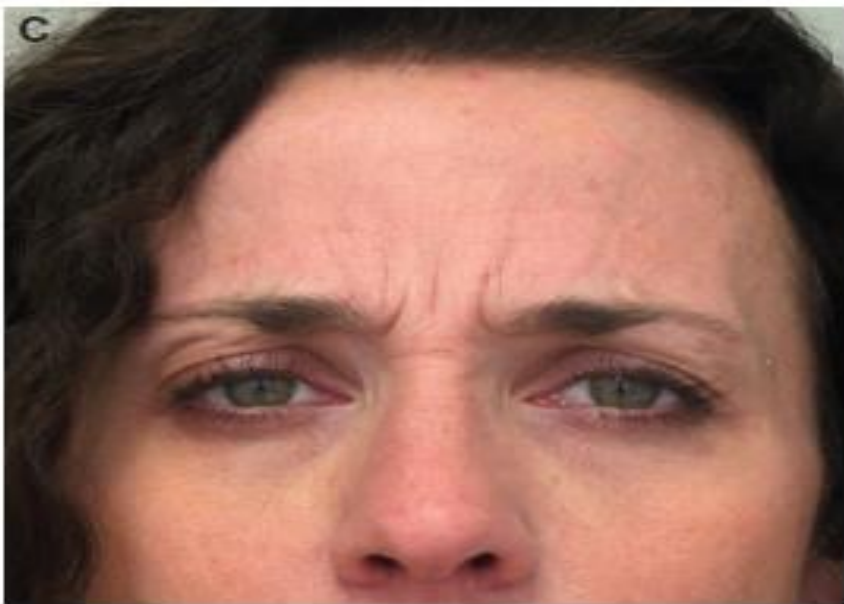
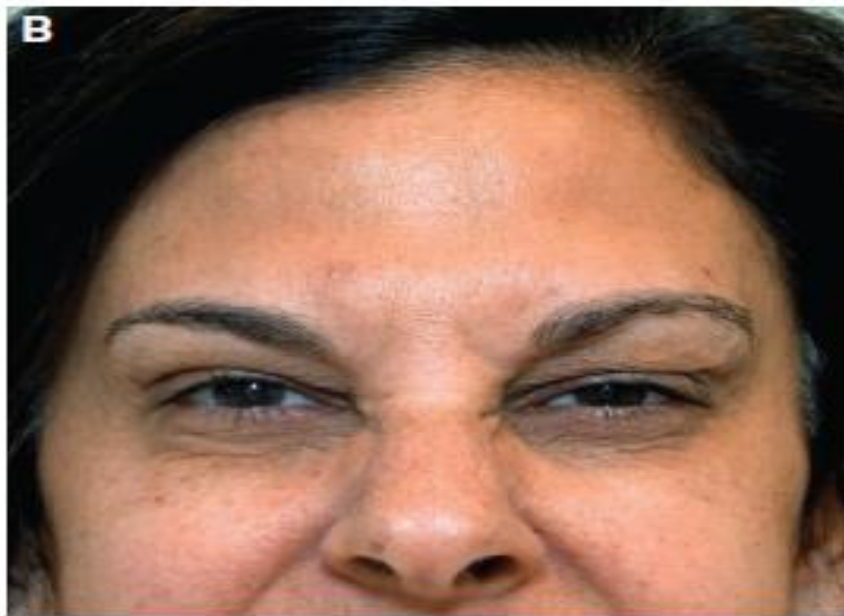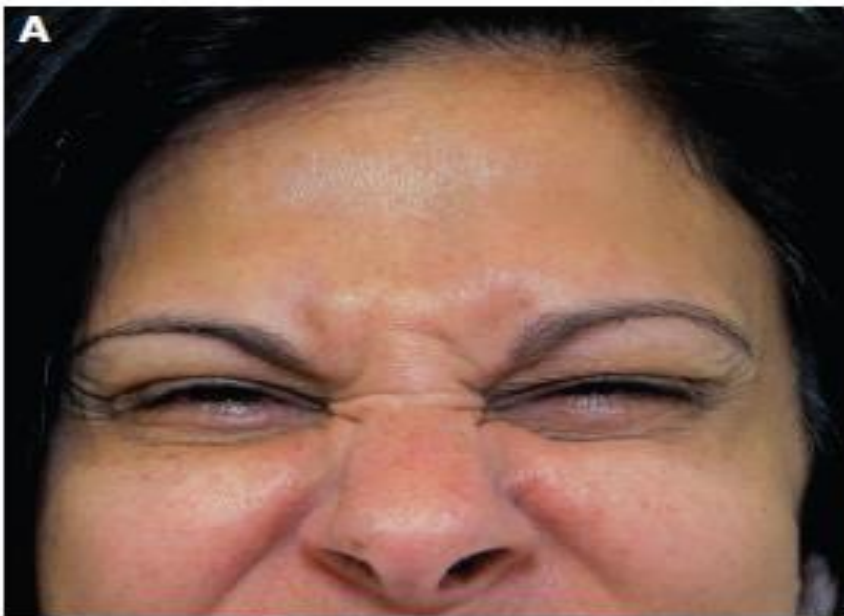Fig. 20-11 A, Before botulinum injection, with contraction of the glabellar muscles. B, After botulinum injection with contraction. C, Before botulinum injection, with contraction of the glabella. D, After botulinum injection on relaxation.

A



Nasalis Muscle

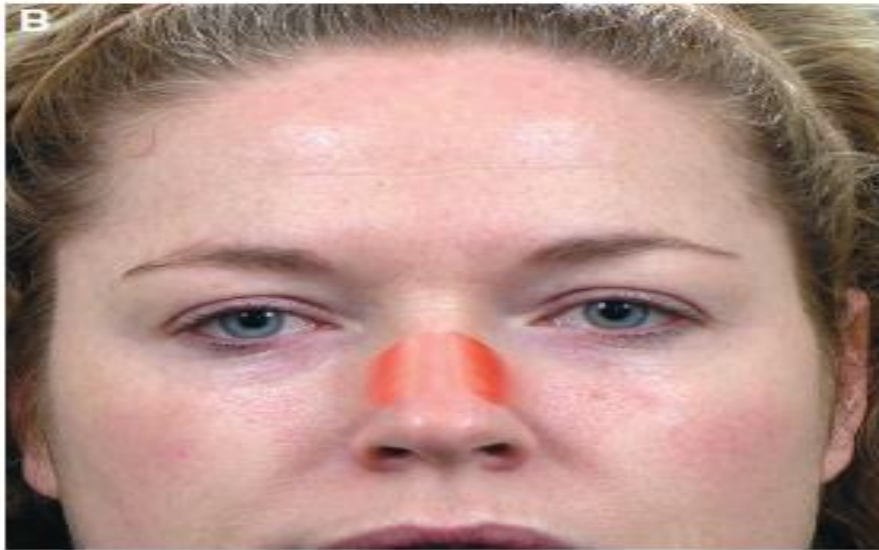

Fig. 20-5 A, Anatomy of the nasalis muscle. B, Overlay showing the location of the nasalis muscle. C, Action of the nasalis muscle (and the glabellar muscles), which causes bunny lines.

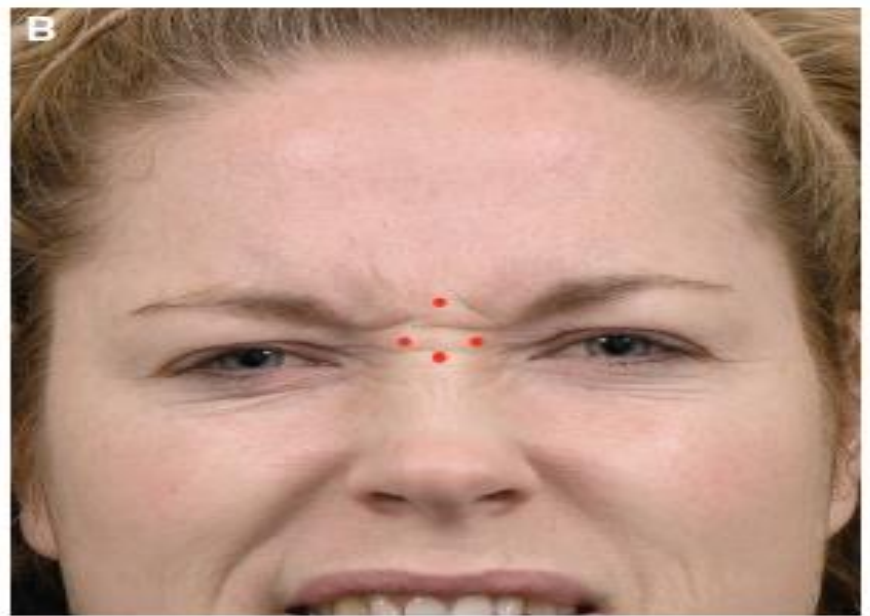


Fig. 20-12 **A**, This patient had bunny lines that appeared on her nose when she was squinting. **B**, The locations of the injection sites to correct the bunny lines are shown. **C**, Three weeks after injection, the patient shows a lack of bunny lines, even when she makes an effort to squint.

Orbicularis Oculi Muscle (Crow's-feet)

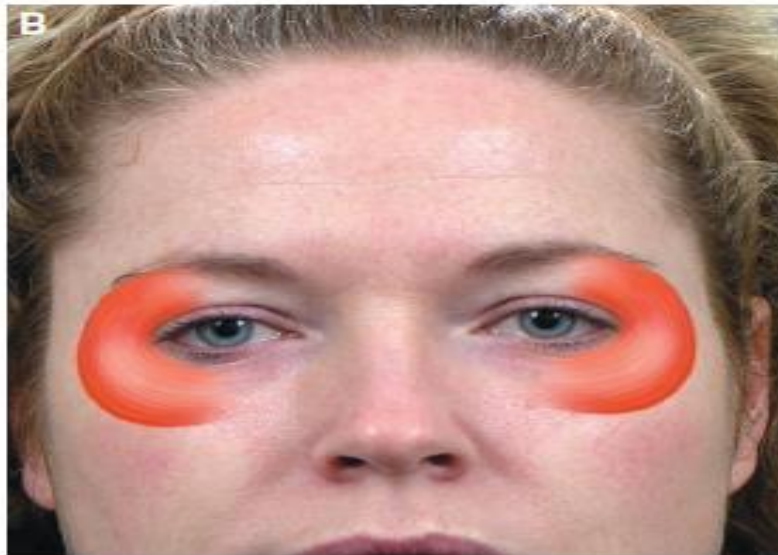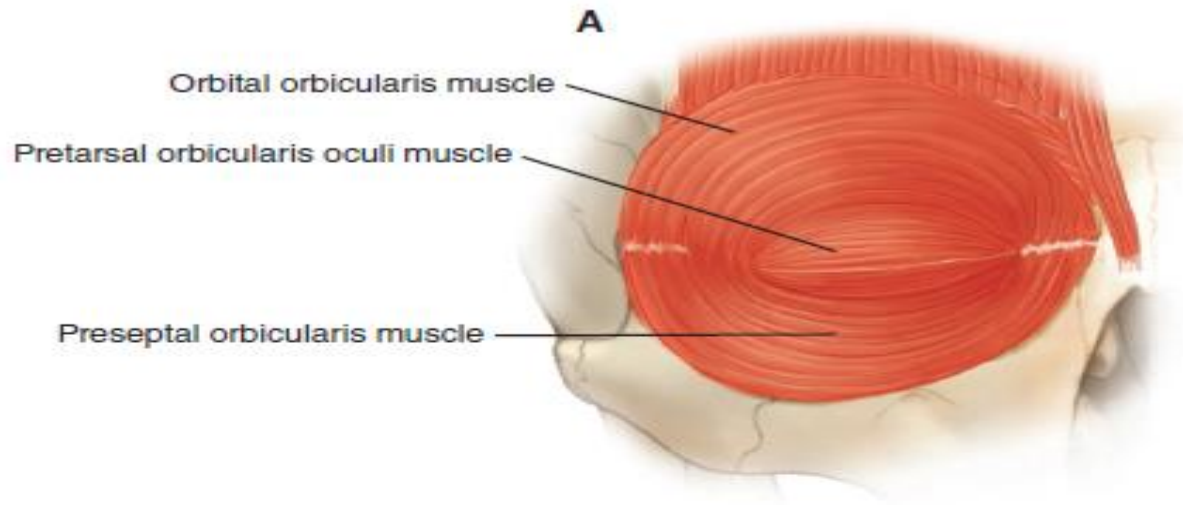
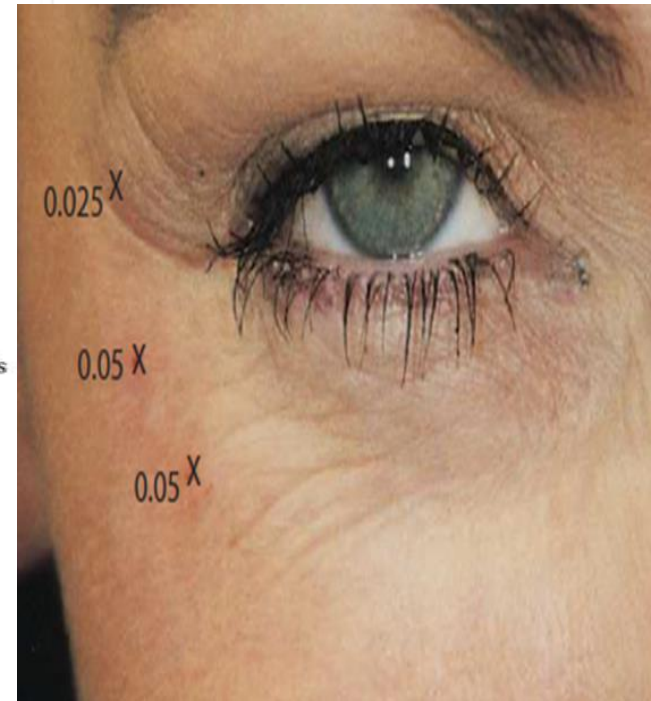
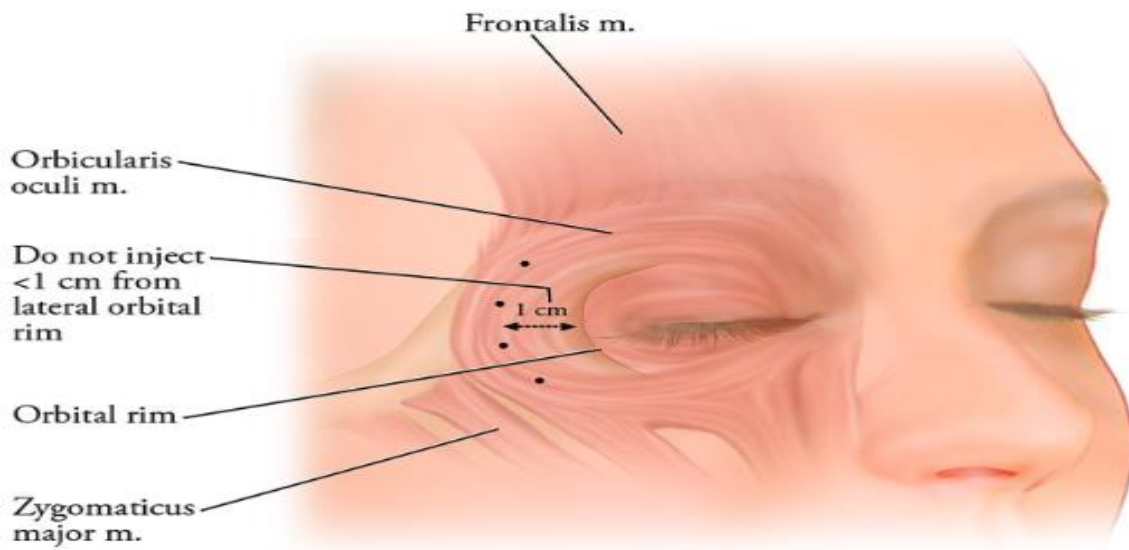
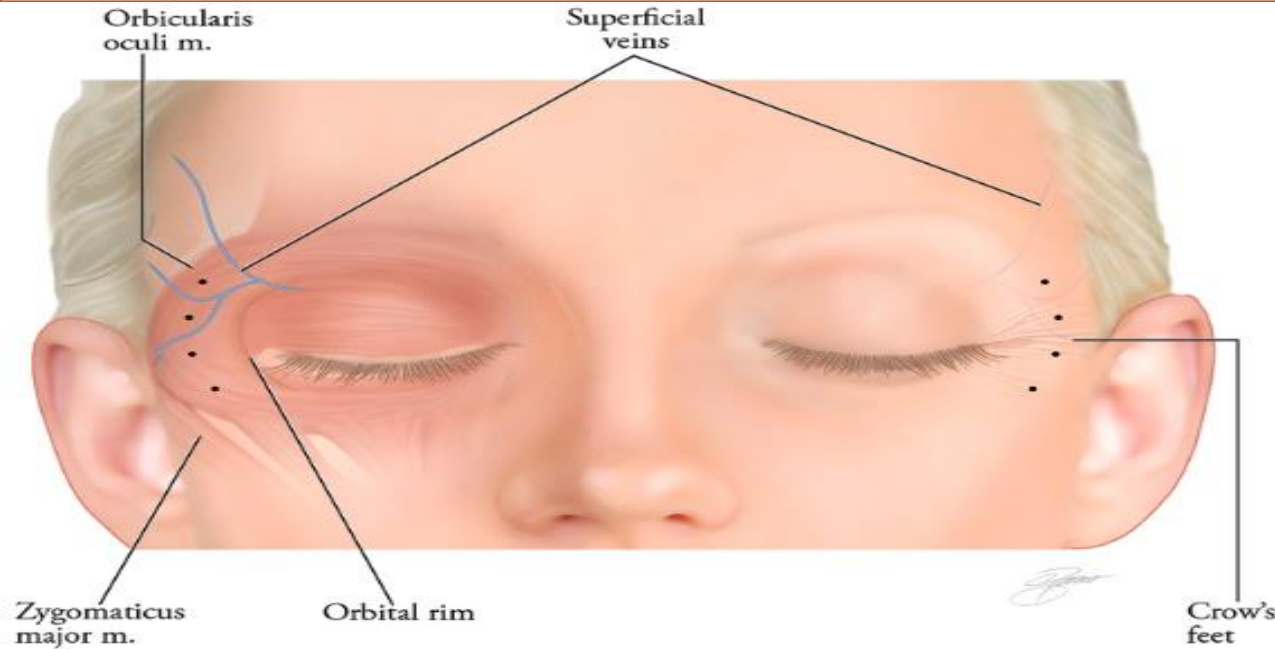


Fig. 20-4 A, Anatomy of the orbicularis oculi muscle. B, Overlay of the lateral orbicularis muscle. C, Action of the lateral orbicularis, which causes crow's-feet.

Injections to treat the crow's feet are traditionally placed subcutaneously into the orbicularis muscle in a radial fashion 1 cm outside the lateral orbital rim, Avoid injection into the superficial veins



CROW'S FEET

Do not inject below zygomatic bone

Inject 1.5 cm lateral to lateral orbital wall or 2 cm lateral to lateral lid canthus

Inject one to four injections of 2.5—5 units/site (total dose 2.5—15 units)

Complications:

Diplopia—if too close to lateral orbital rim or lateral canthus

Treat with Fresnel prism

Ectropion—if too close to lower lid canthus

Treat with topical lubrication, tape, temporary suture

Lid Ptosis—if too close to lateral orbital rim

Treat with Iopidine (Alcon, Ft. Worth, TX)

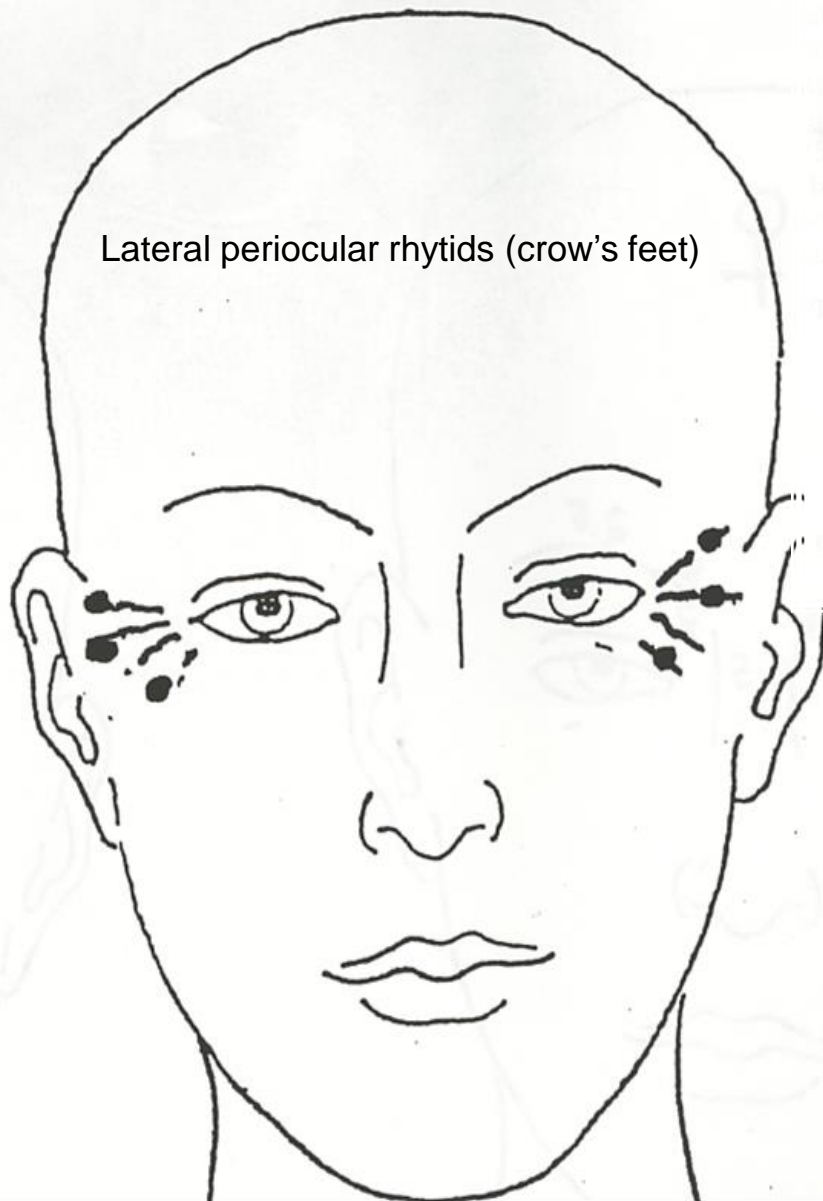
Adjunctive Procedures:

Skin Rejuvenation (chemical, dermabrasion, laser) 2 weeks post BOTOX

Lateral Canthal Lift

Lower or Upper Lid Blepharoplasty

Midface, Cheek or SOOF Lift



Lateral periocular rhytids (crow's feet)

3 units of BTX per/site
10 units dysport per /site

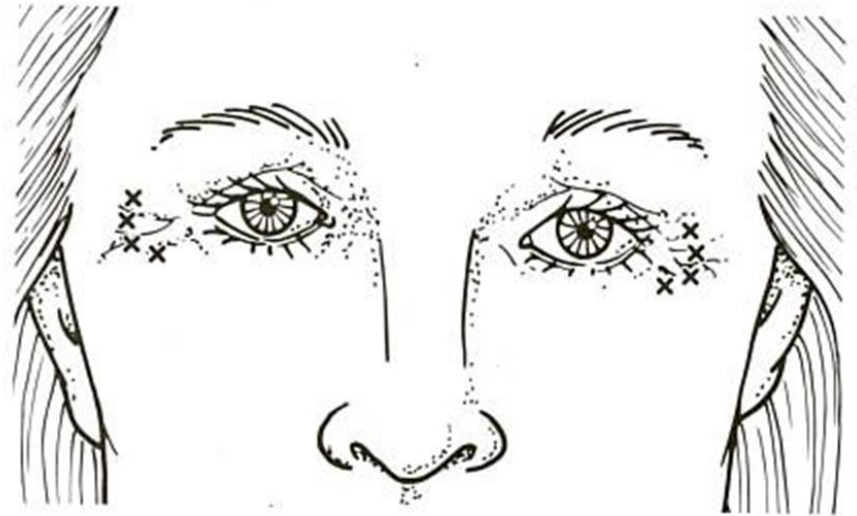
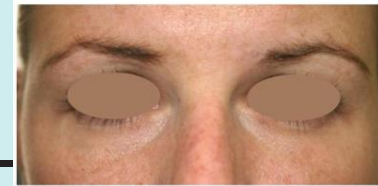
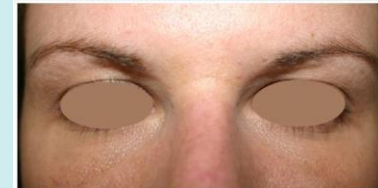
Table 7.1. Categories of crow's feet and their treatment



Before Treatment



8 Weeks After

Type of crow's feet

Management

Wrinkles in motion

Botulinum toxin

Fine lines at rest

Botulinum toxin, collagen stimulation

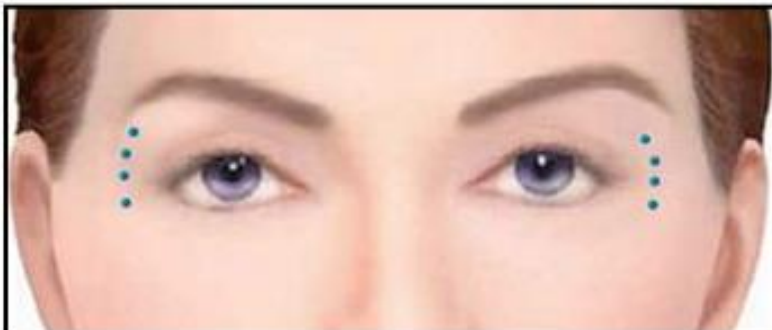Deep wrinkles at rest

Botulinum toxin, laser resurfacing, coblation

Deep wrinkles at rest with hooding

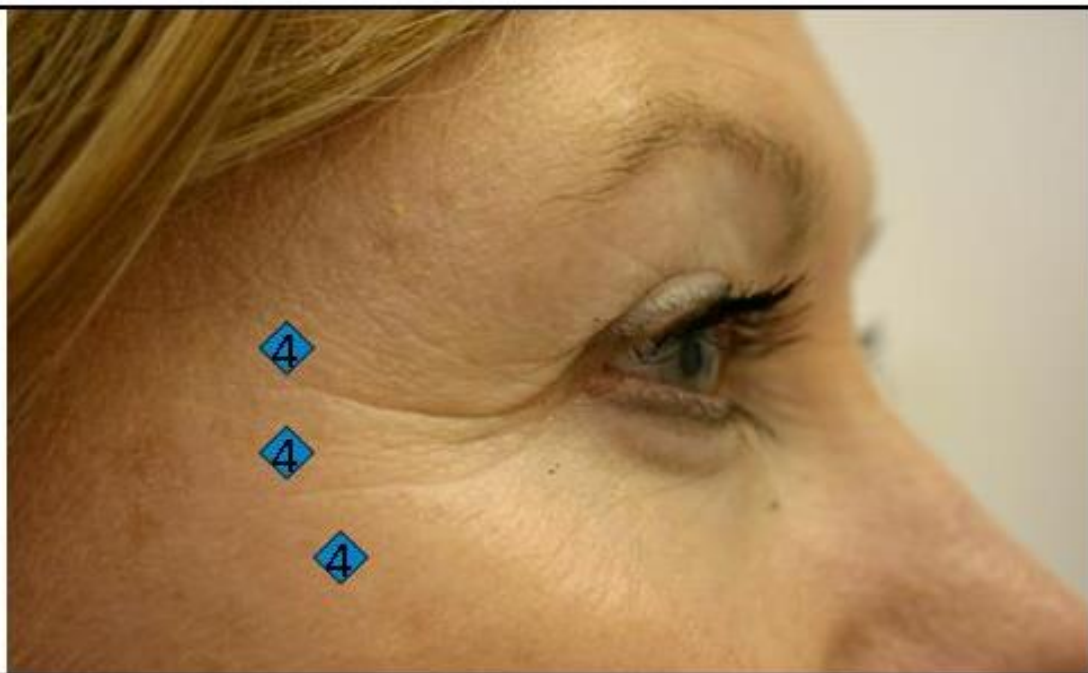
Botulinum toxin, laser resurfacing, hyaluronic acid, brow repositioning.

Treating Crow's Feet With Botulinum Toxin-A (BTX-A)

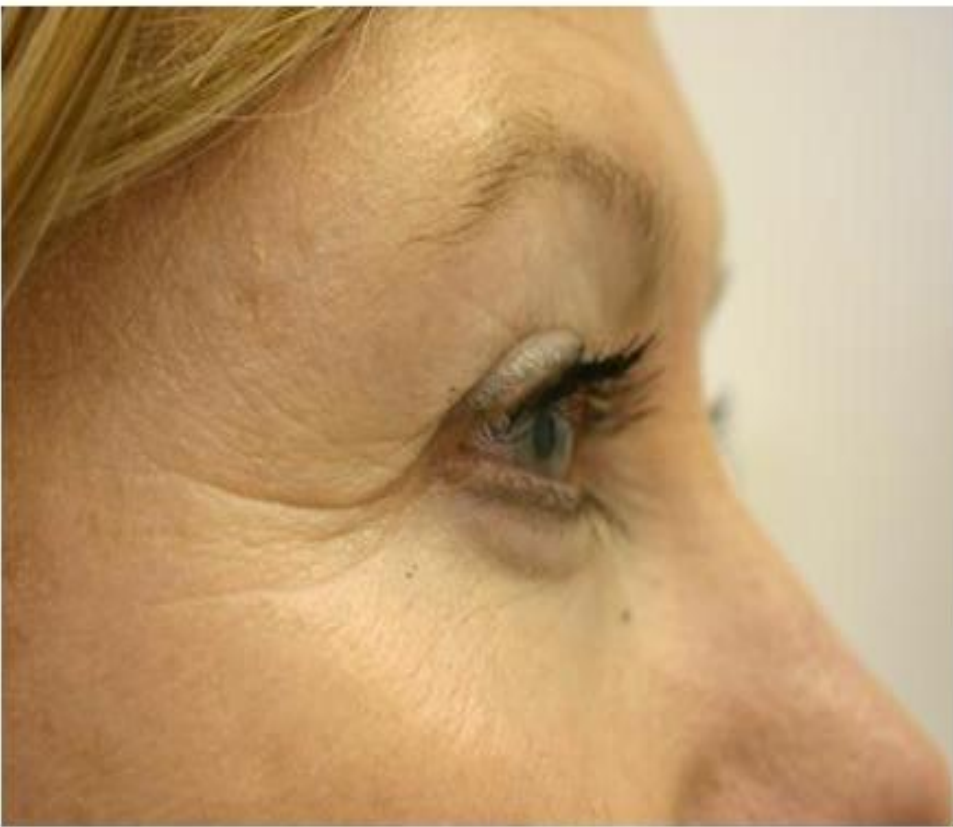

Botox treatment of the lateral orbital rhytides is off-label

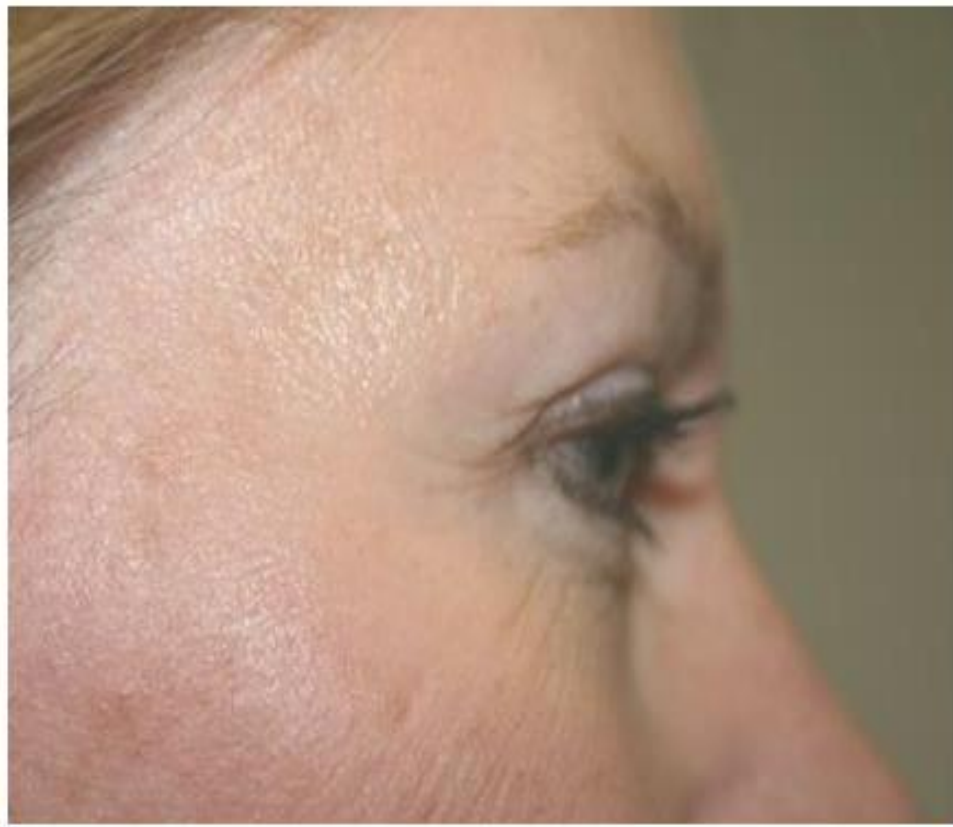Inject Botox lateral to orbital rim into lateral Orbicularis, to avoid lower eyelid droop and preserve ability to close eyelids forcibly



Treating Crow's Feet With BTX-A



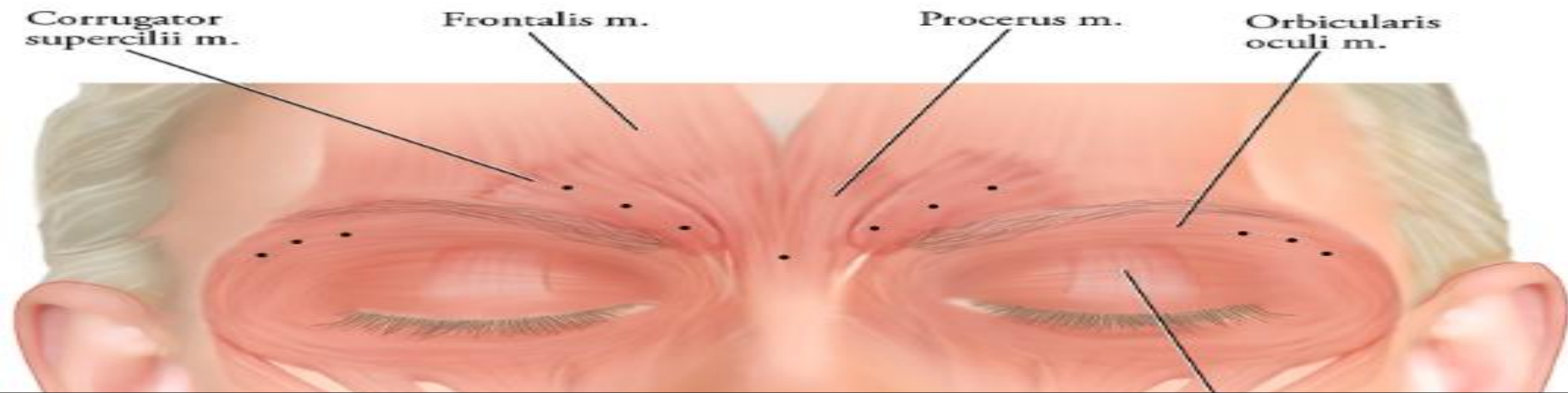
At Rest Before Botox



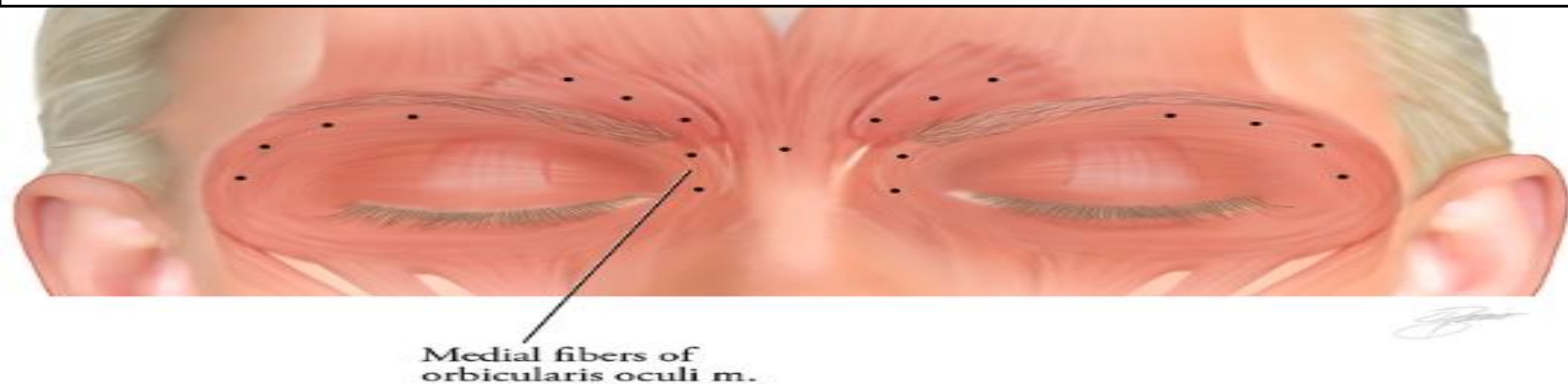
At Rest After Botox

chemical brow lift

can be produced by treating the procerus and corrugator muscles centrally and the orbicularis oculi muscle laterally.



The frontalis muscle must not be treated so that it can take over the upward pull of the brow



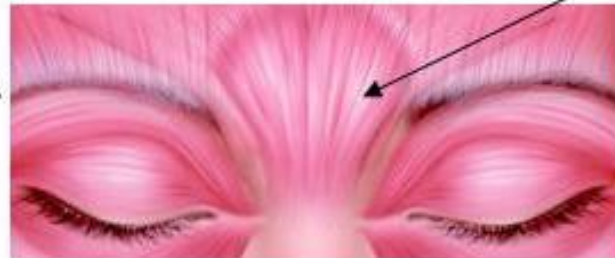Brow Lifting and Shaping With BTX-A

LATERAL BROW DEPRESSOR

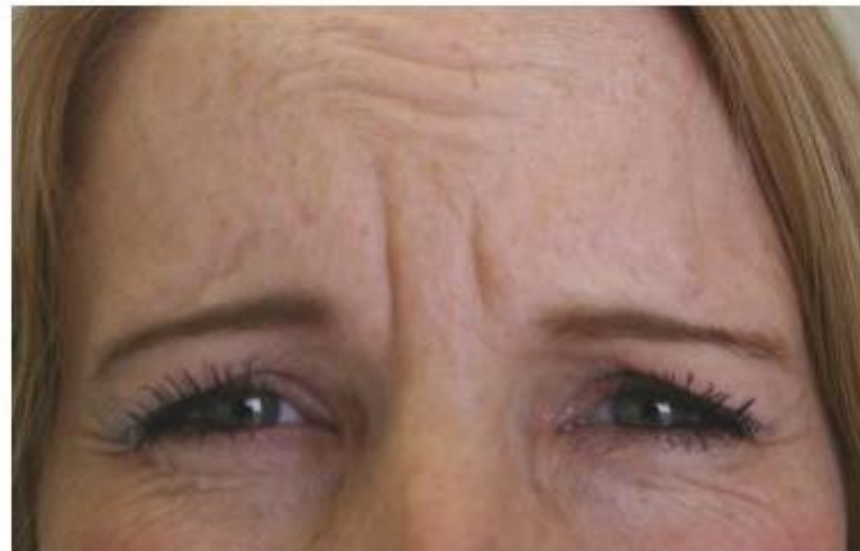Lateral portion of orbicularis
Inject Botox subdermally

MEDIAL BROW DEPRESSORS

Procerus, corrugator supercilii,
Medial portion of orbicularis



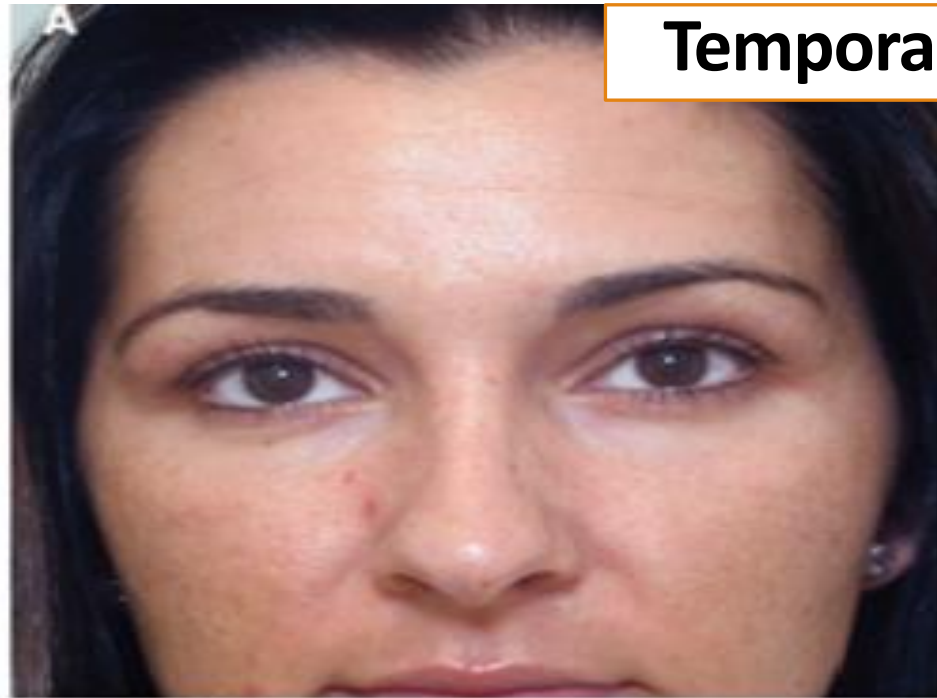Botox-mediated
weakening of
brow depressors
allows unopposed
brow elevation by
frontalis



Brow Arching:

Less Botox
higher over mid-
brow,
more Botox
lower over
medial and
lateral brow

Temporal Brow Lift



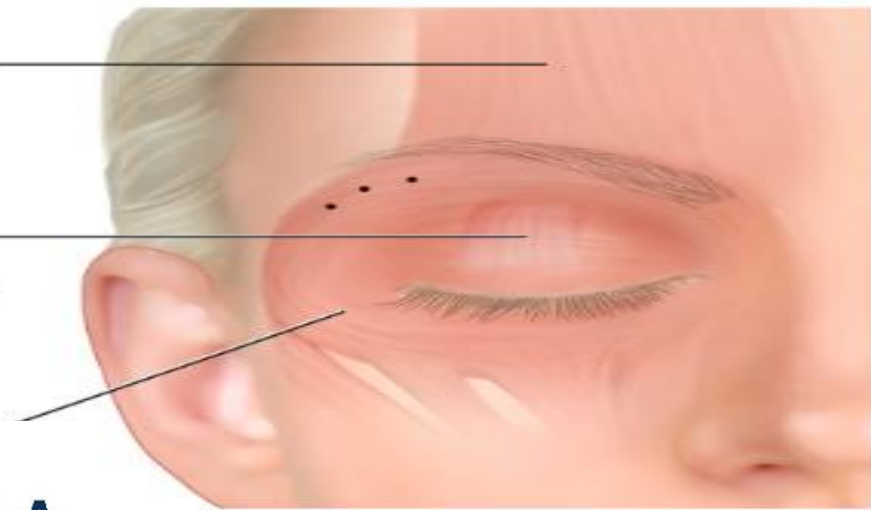
Injection into this area is immediately **subdermal**, because **deeper injection** can cause a spreading of neurotoxin to the levator muscle, which results in **blepharoptosis**.

For the treatment of this muscle, **10 to 15 units of neurotoxin** are injected in divided doses 2 cm lateral to the lateral canthus

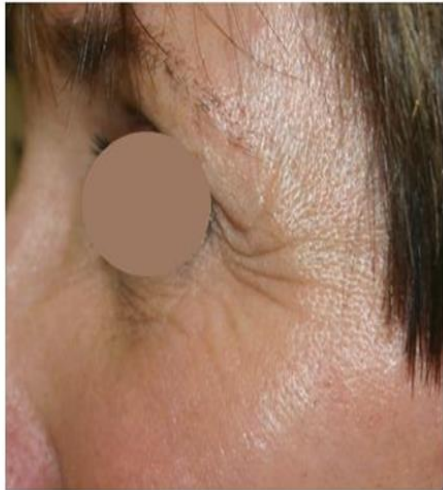Temporal Brow Lift

Frontalis m.

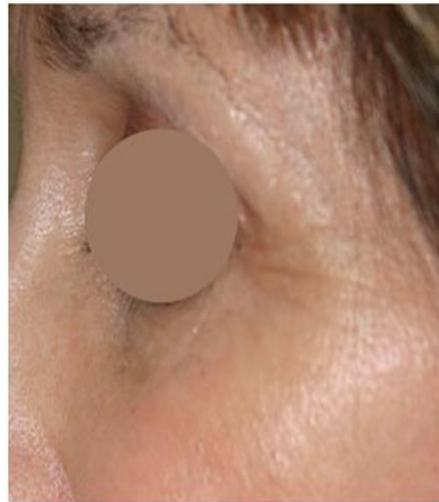Levator palpebrae superioris m.



Periorbital NASHA Filler and BTX-A

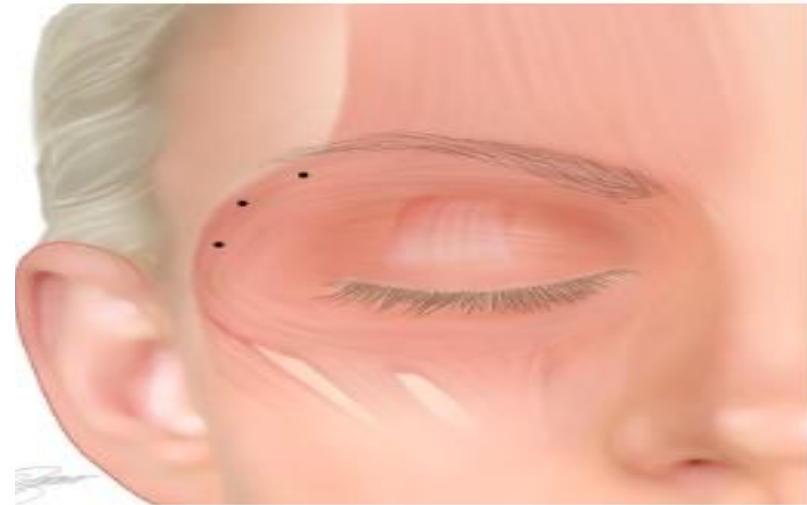

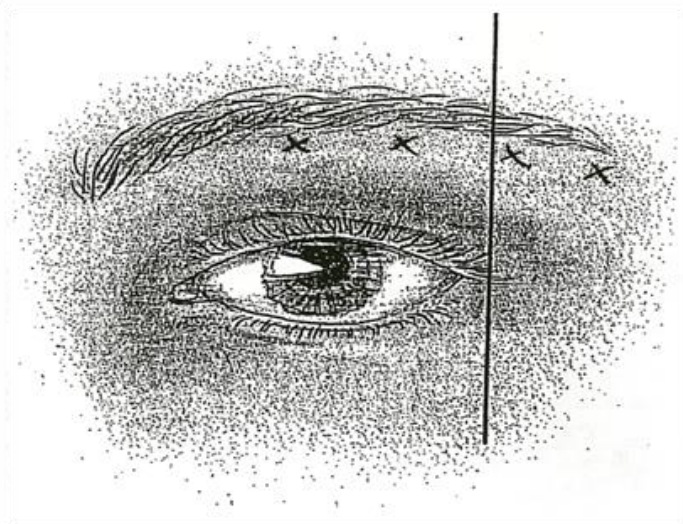
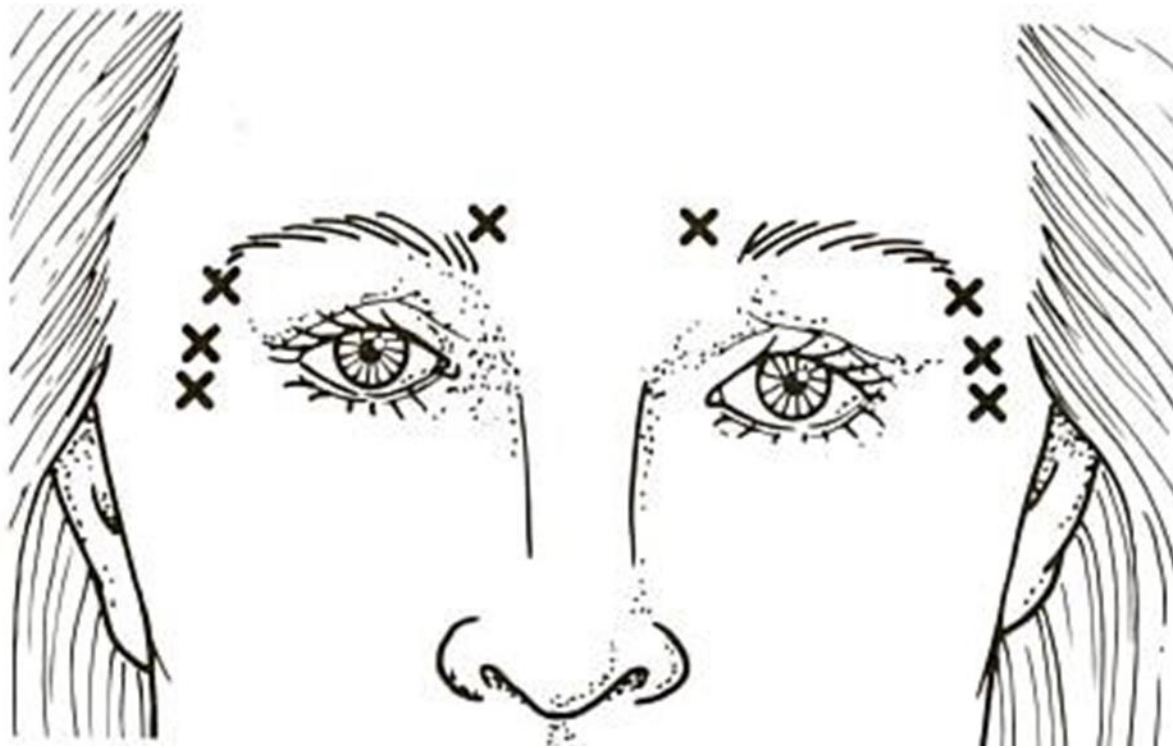
Before Treatment



2 Weeks After

- Restylane to lower eyelid, brow and superolateral midface
- Perlane to superomedial midface
- Botox to lateral orbital rhytides and Botox brow lift





Brow reposition

2.5 units BTX or 8 units dysport per/site in three lateral sites
Medial injection 5 to 10 units BTX or 15 to 30 dysport

BROW ASSYMETRY

Lateral Brow Ptosis often due to Frontalis being injected lateral to mid-pupil line

Lateral Brow depressors are stronger than brow elevator (frontalis)

Inject into Orbicularis Oculi, just inferior to orbit margin in lateral half of brow

Inject very superficial (subcutaneously rather than into muscle)

2.5 units/site for 2-4 sites

May increase brow height by 2- 4 mm centrally and 1-5 mm laterally

Complications: as for Glabella and Crow's Feet

Adjunctive Procedures: as for Glabella and Forehead

The lower lid pretarsal orbicularis hypertrophy may also be injected to open the ocular aperture. Typically, this requires only one or two injections of 1 unit of Botox. Overinjection carries a risk of excessive scleral show.

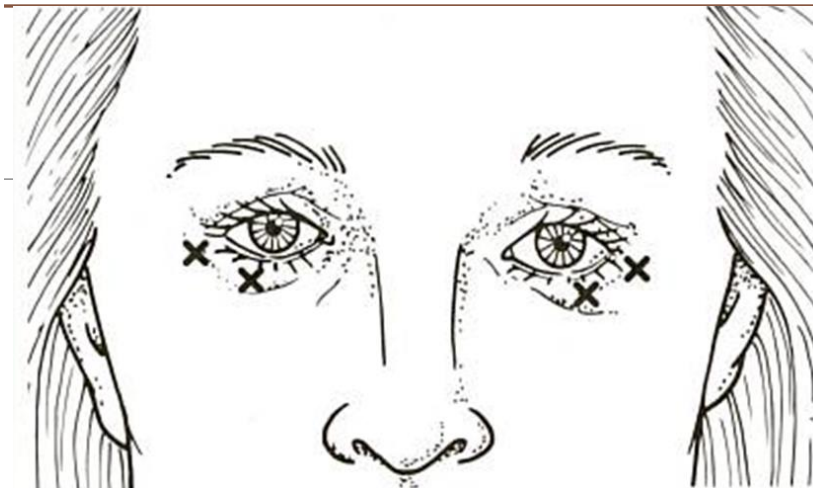
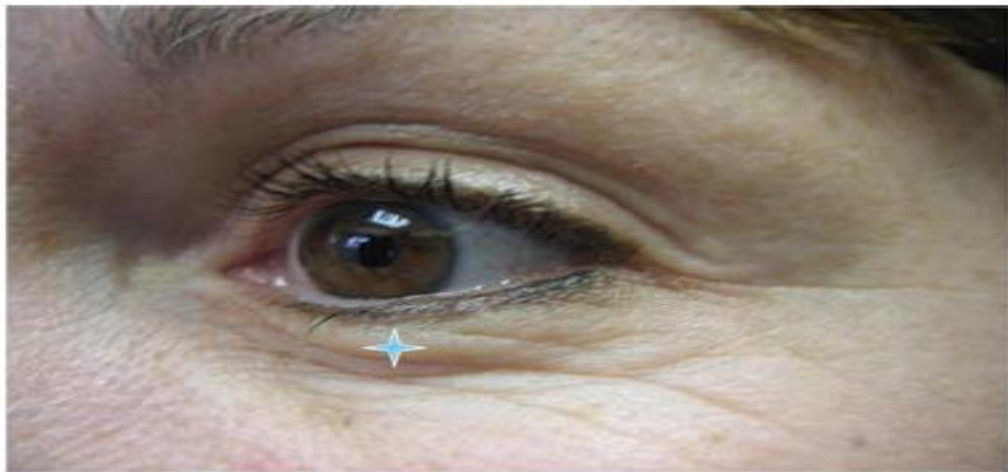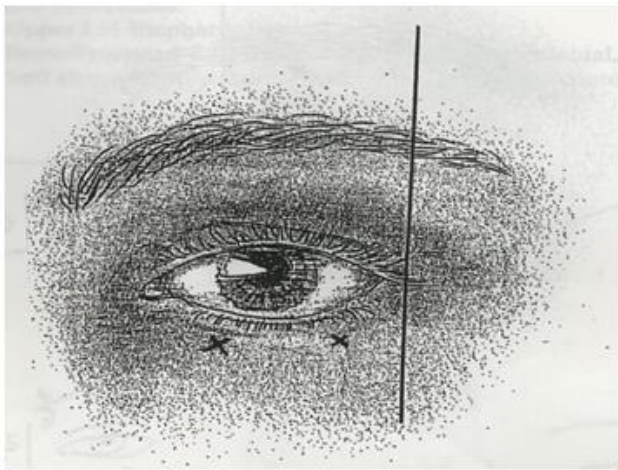


Figure 5.5 Location of lower palpebral injection. A tiny dose of toxin into the lower eyelid can create a more youthful “open” eye (2 s.U. or 0.5–1 b.U.).

Hypertrophic orbicularis
0.5 units BTX or 1.5 units dysport per/site



ORBICULARIS HYPERTROPHY

Aim is to soften lower lid lines

Inject very superficial (subcutaneously), just under skin and superficial to muscle
Inject 1-2 units at 2 sites/lid, 4 mm below lid margin, central and lateral lid

Complications: as for Crow's feet and Glabella

Contraindications:

Dry Eye

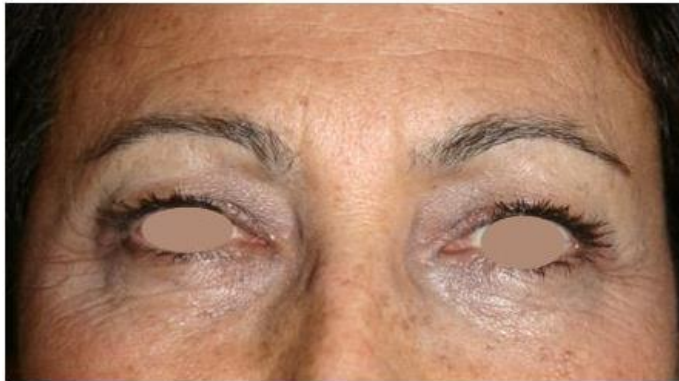Lower Lid Ectropion, Retraction, or laxity (snap test)

Facial Palsy

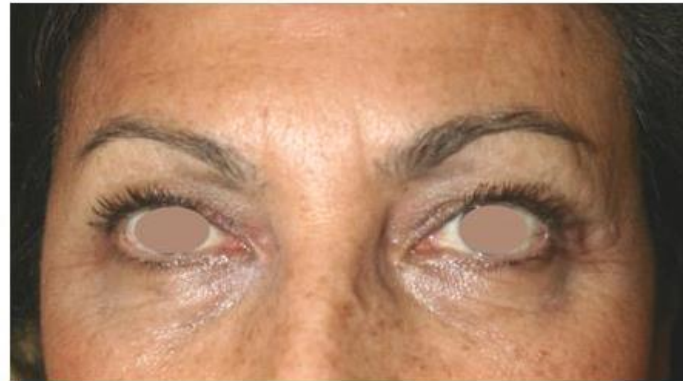Eyelash malposition like trichiasis

BOTOX treatment to Lid within 6 months

Eye Opening and Brow Shaping

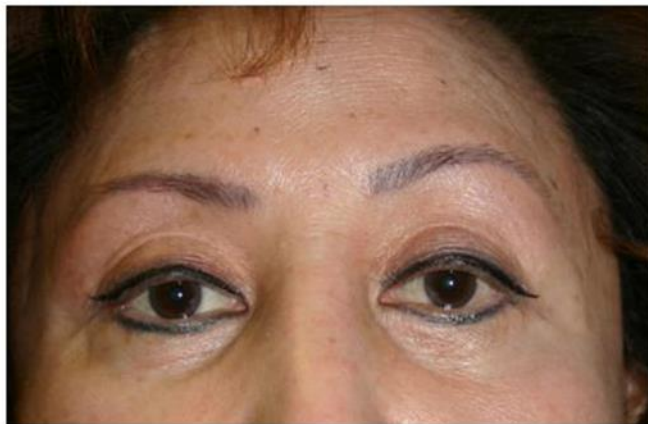

Before Botox

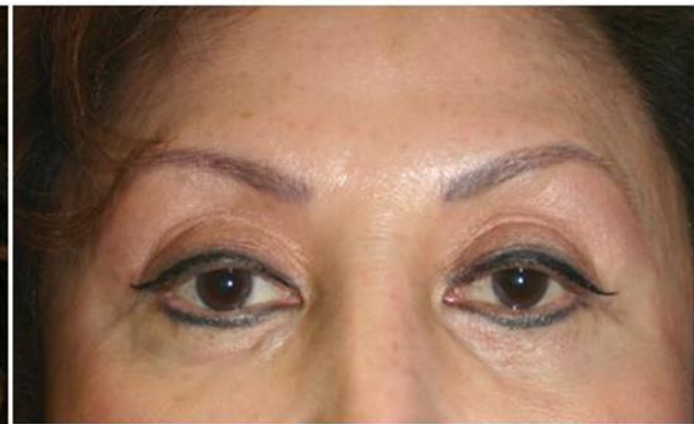

After Botox

Improvement of Eyebrow Ptosis With BTX-A and NASHA Filler

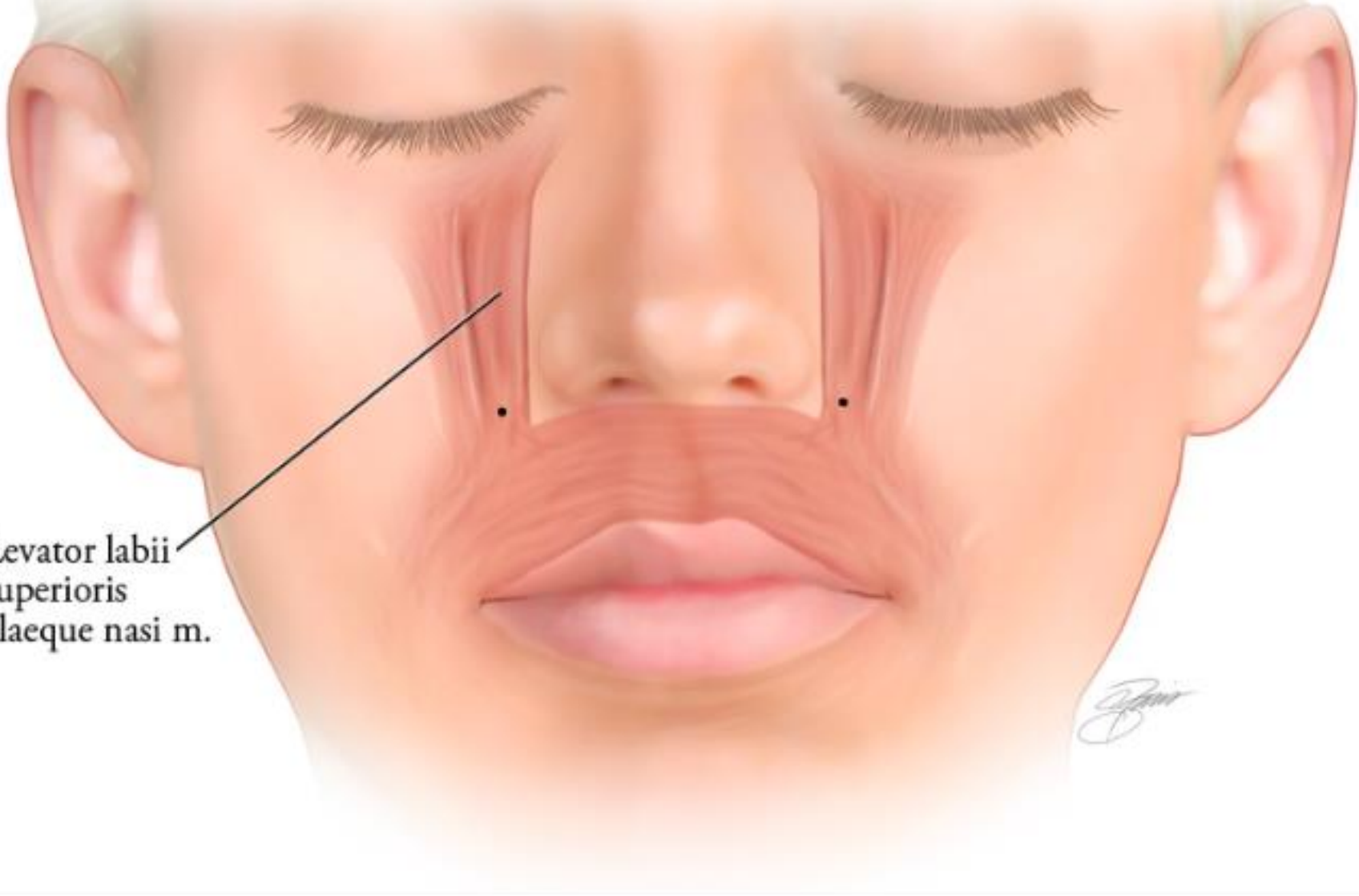


Before Treatment



After

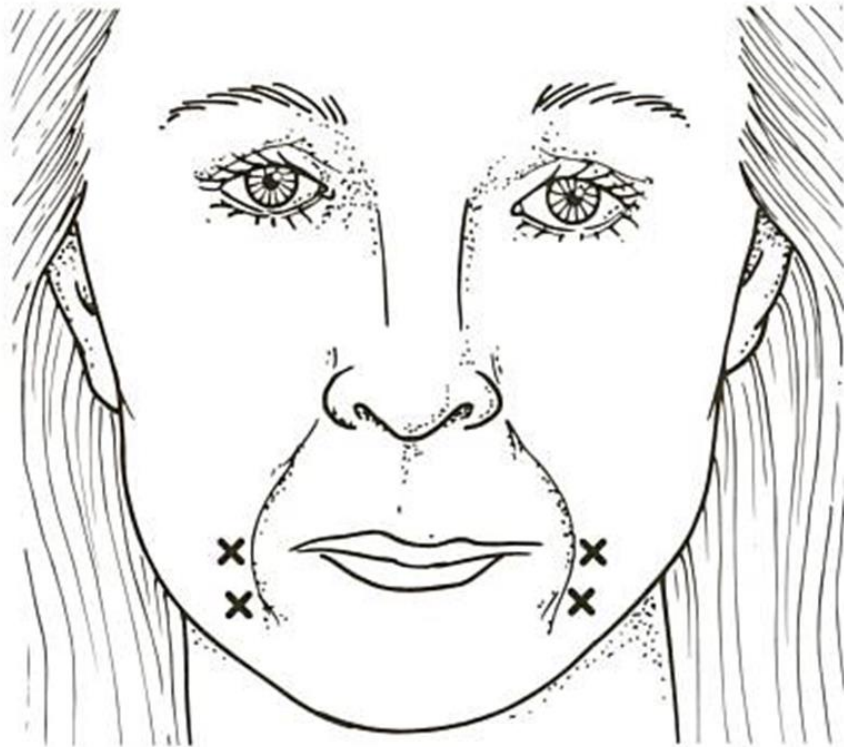
Gummy smile



Levator labii
superioris
alaeque nasi m.

Fig. 18.1 Injection of BoNTA into the inferior aspect of the levator labii superioris alaeque nasi muscle will decrease the upward pull on the lip when the patient smiles.

Injection technique for perioral wrinkles , melolabial folds, neck wrinkles, and platysmal bands



Melolabial folds
1 unit BTX or 3 units dysport per/site

Perioral wrinkles
0.5 unit BTX or 1.5 units dysport per/site

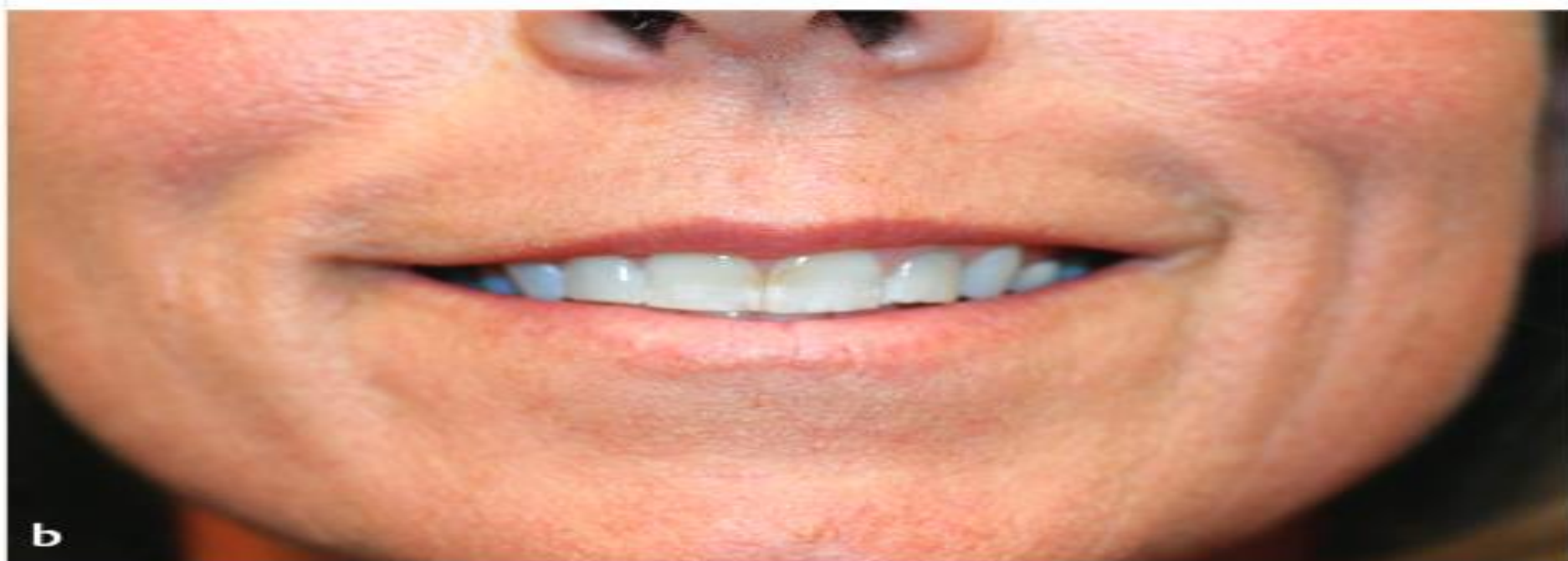
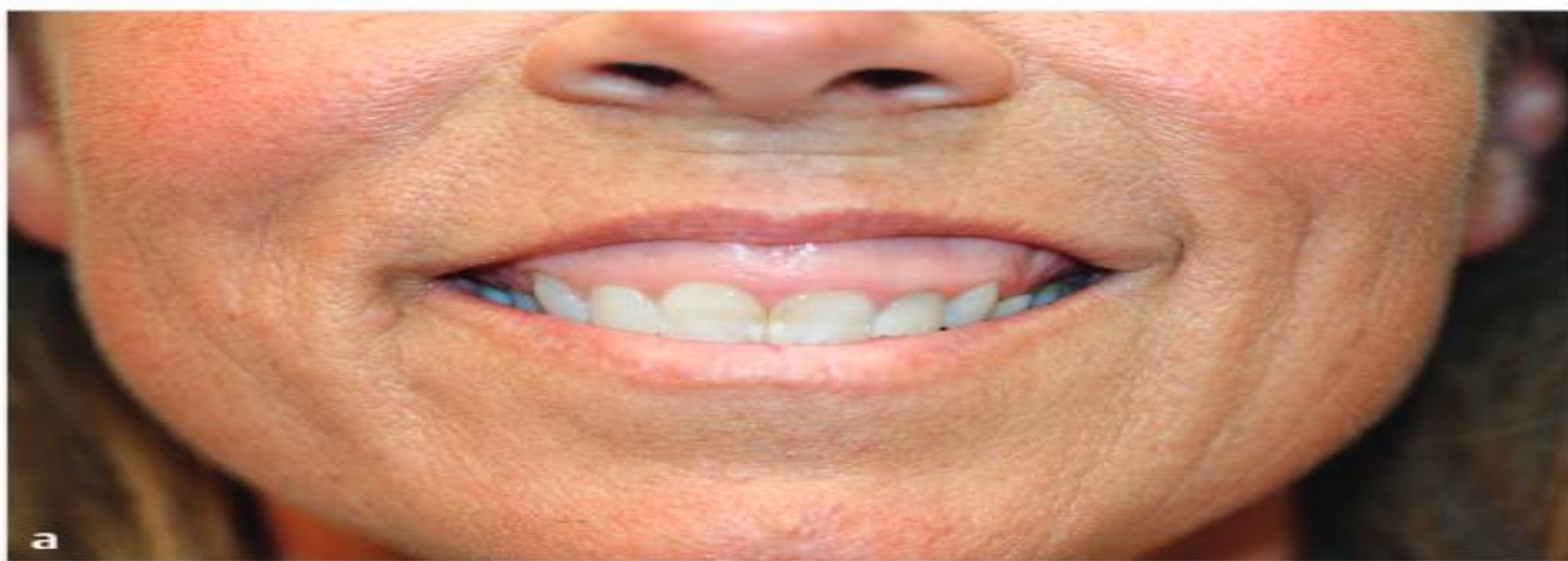
Fig. 18.2 (a) Patient with gummy smile pre-injection. **(b)** Post-injection BoNTA with patient producing maximum smile excursion. Also note improvement in the horizontal crease below the columella.

PANEL DISCUSSION



“تزریق بوتاکس اطراف چشم و صورت”

Points for Cosmetic Facial Botox Thx? Expert Comments!

Panelists:



Abrishami M, MD



Bahmani Kashkouli
M, MD



Karimi N, MD



Khademi B, MD



Jafarpoor S, MD

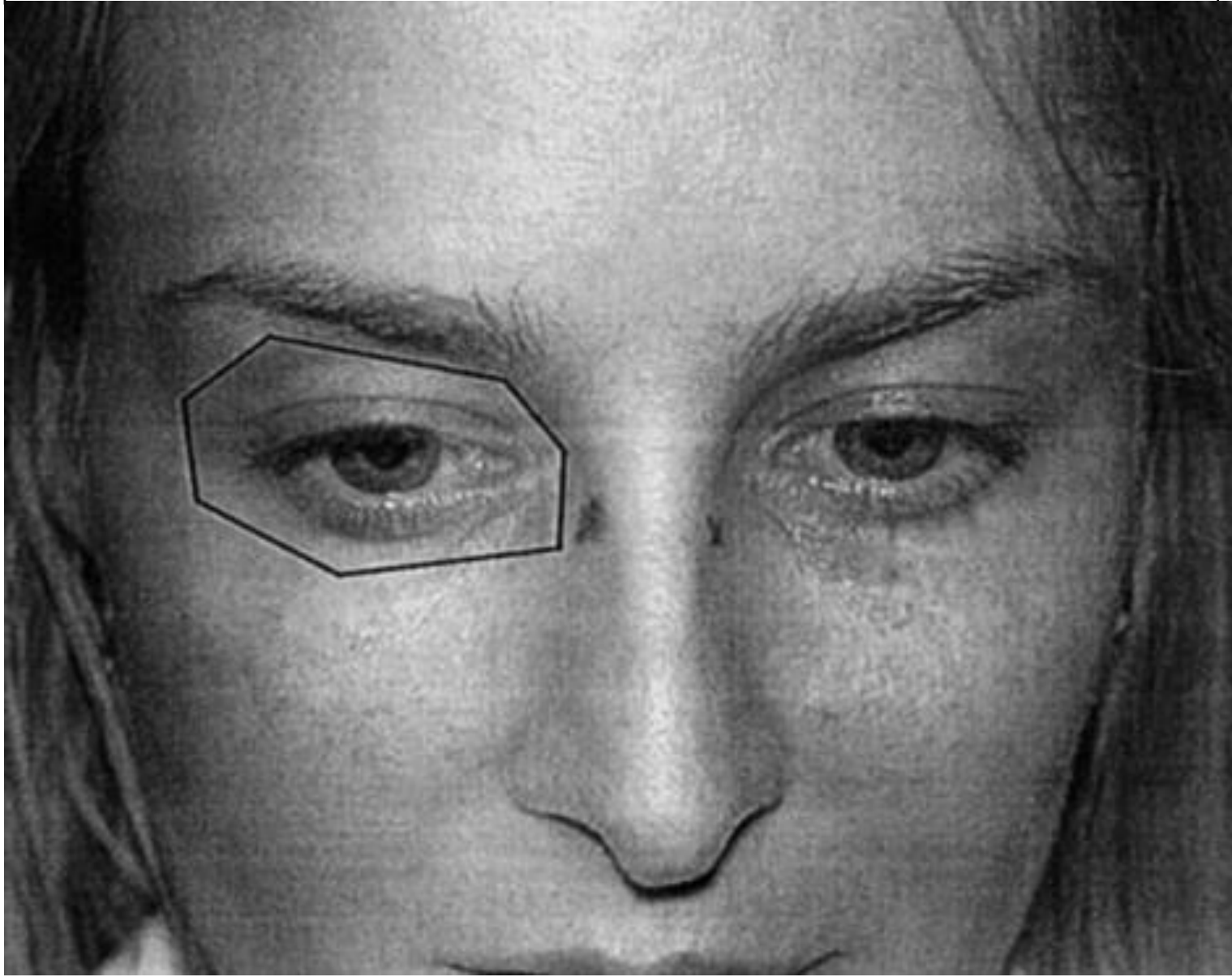
In the name of God

Complications of Facial BOTOX

Mohammad Abrishami M.D.

Labbafinejad Medical Center
Shaheed Beheshti University of Medical Sciences

Orbital zone for minimize preorbital complications



Injection pain

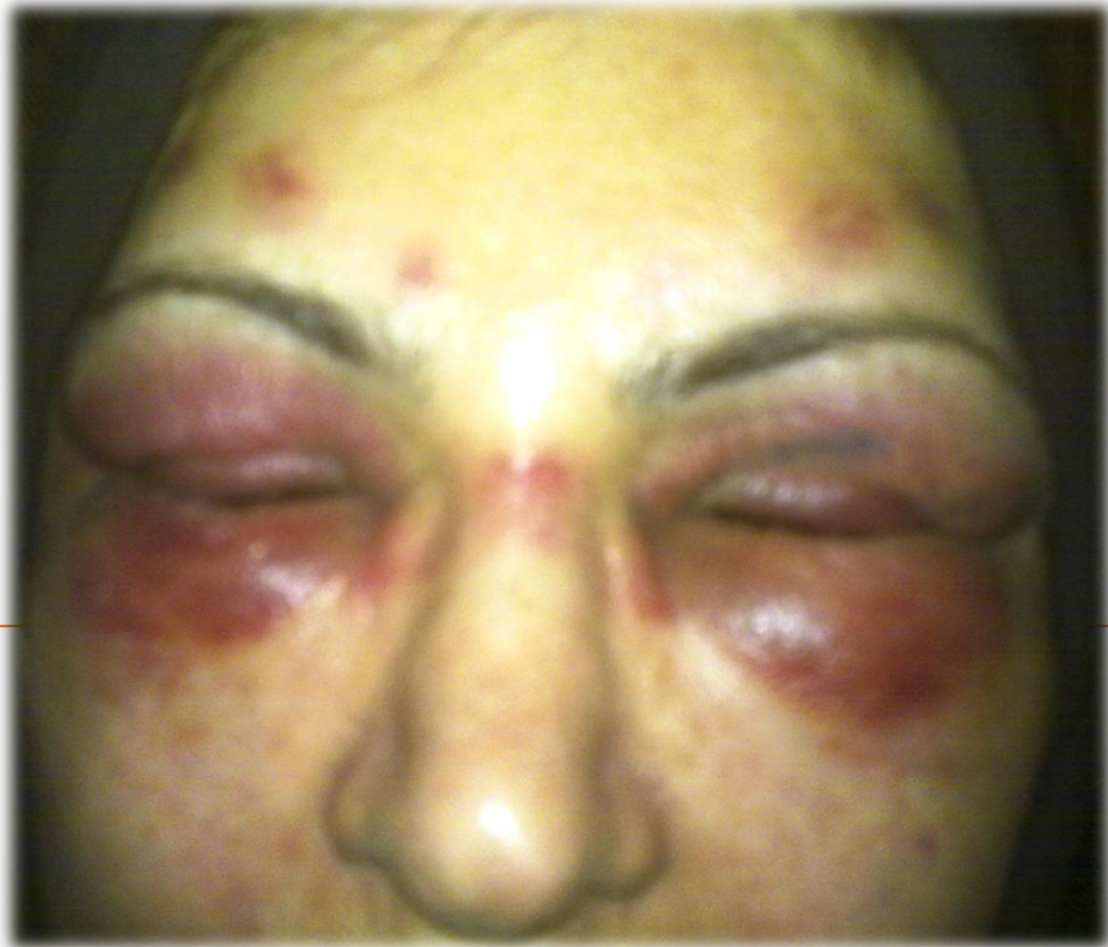Decrease pain with :

- ✦ **EMLA cream**
- ✦ **Cool Packs**
- ✦ **Lidocaine 2.5% + Prilocaine 2.5%**

Hematoma and Bruising

Risk Factors :

- Anticoagulant drugs
- NSAID
- Vit.E
- Ginseng
- High doses of Garlic



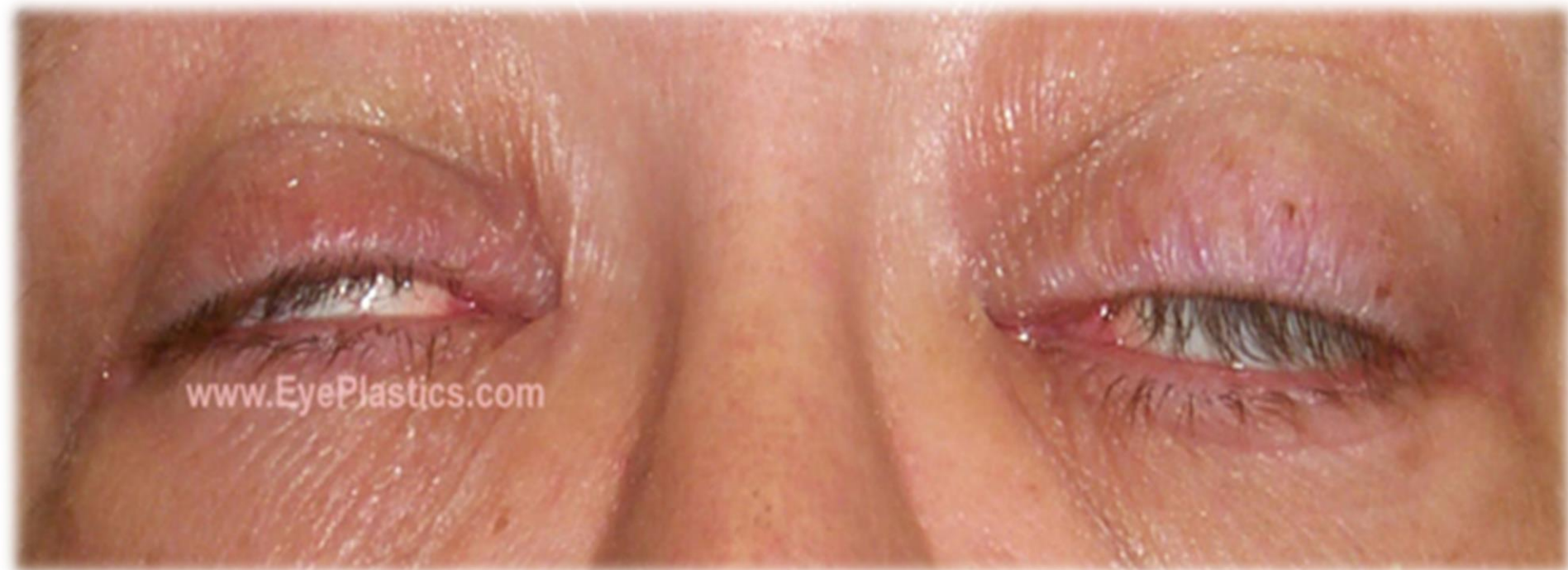Headache

- **Rate 0-30%**
- **Duration**
 - Few hours**
 - 2-4 weeks (1% Pt.)**

Dry eye

up to 36%

Lagophthalmous



Localized skin dryness

Male > Female

- **Rate 3-8 %**
- **Rec. use skin moisturizers**

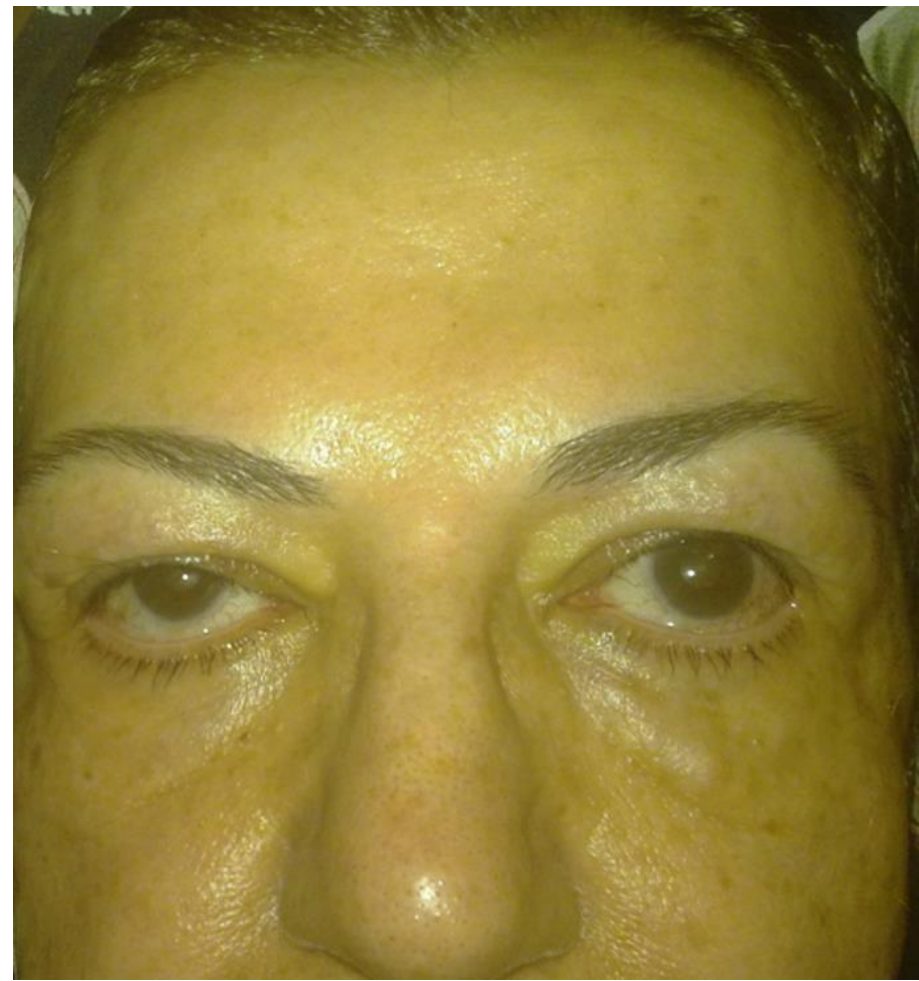
Eyelid ptosis

Etiology :

**Injections to Orbicularis,
Corrugator and**

Procerus muscles

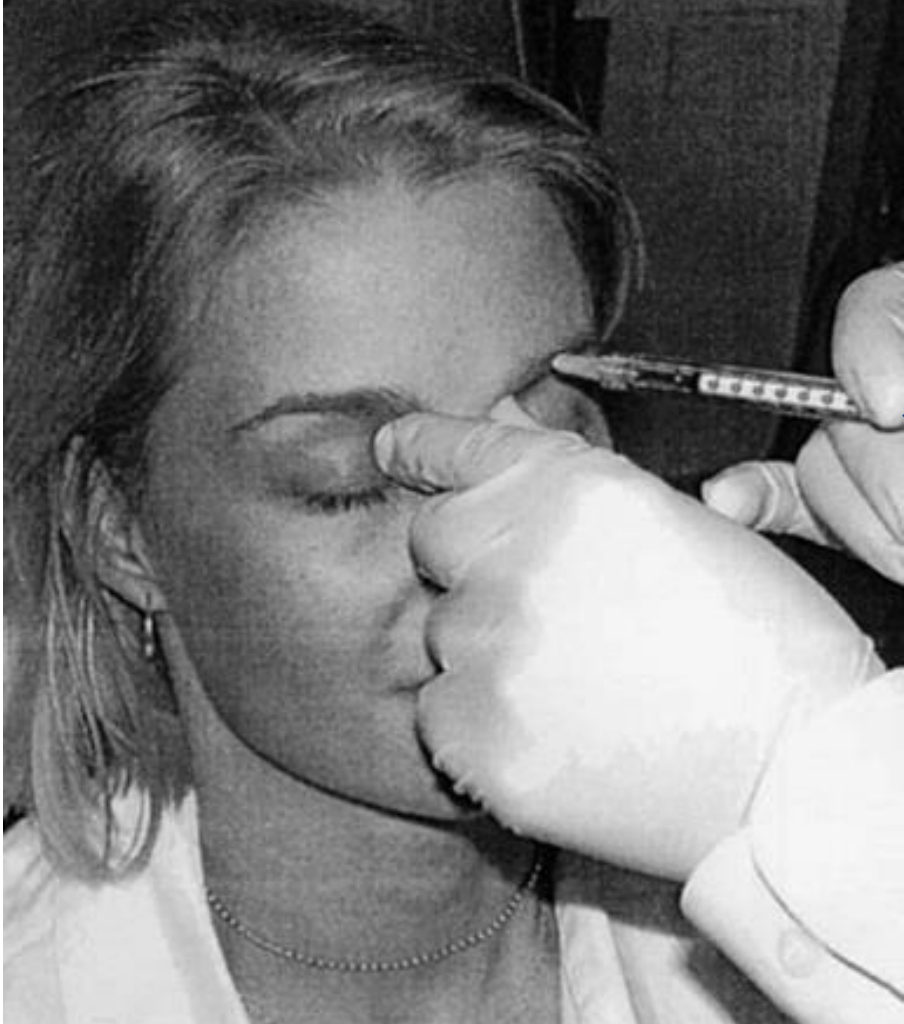
- **Unrecognized
subclinical eyelid Ptosis**



- **Onset (2-7)days**
- **Rate (2-20%)**
- **Resolves (2-6 weeks)**

Reducing Blepharoptosis

Injecting at least 1cm above the supraorbital ridge



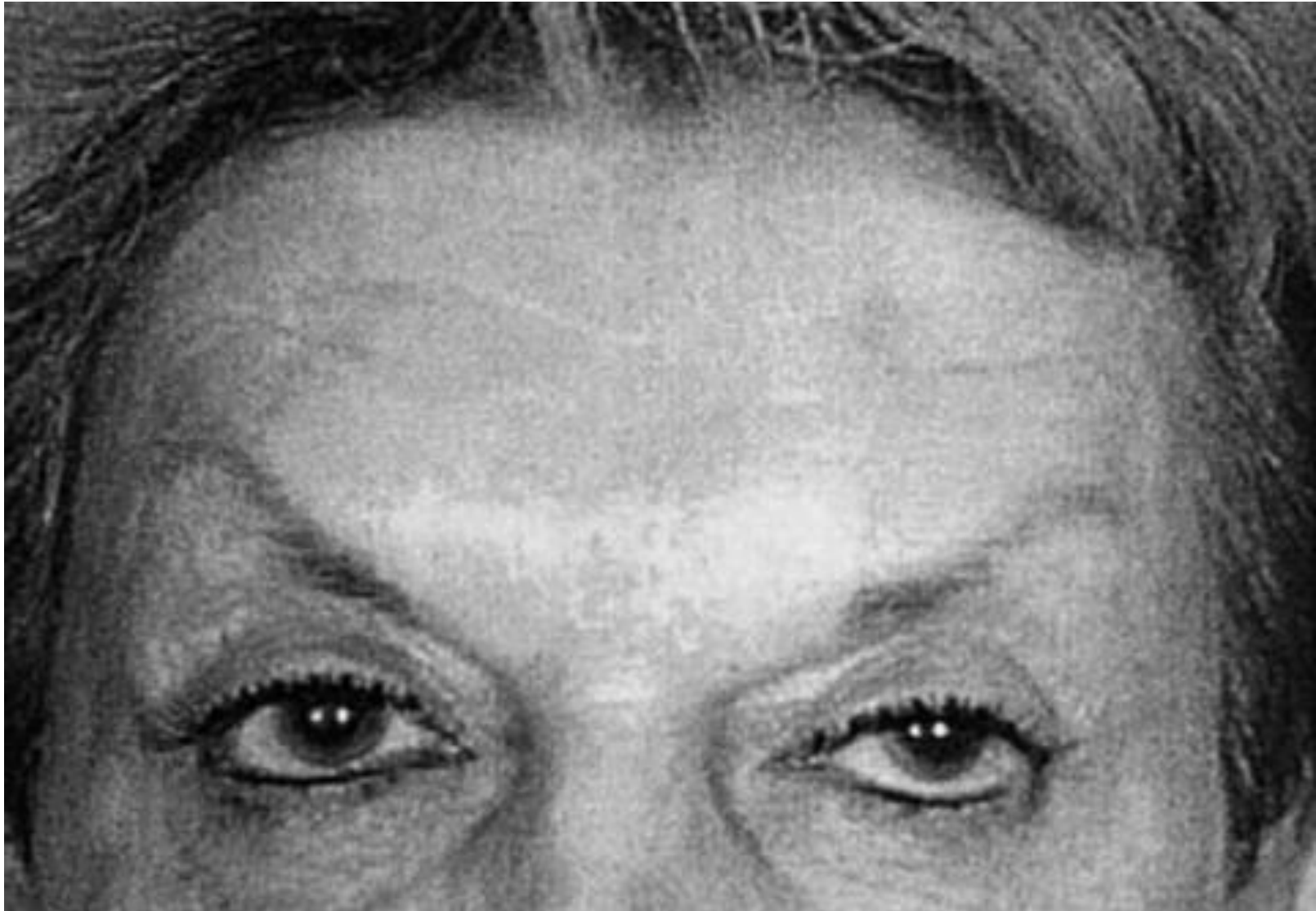*Direct digital
pressure in
adjacent areas*

Treating Post Botox Ptosis

Responds to Alpha-adrenergic agonist :

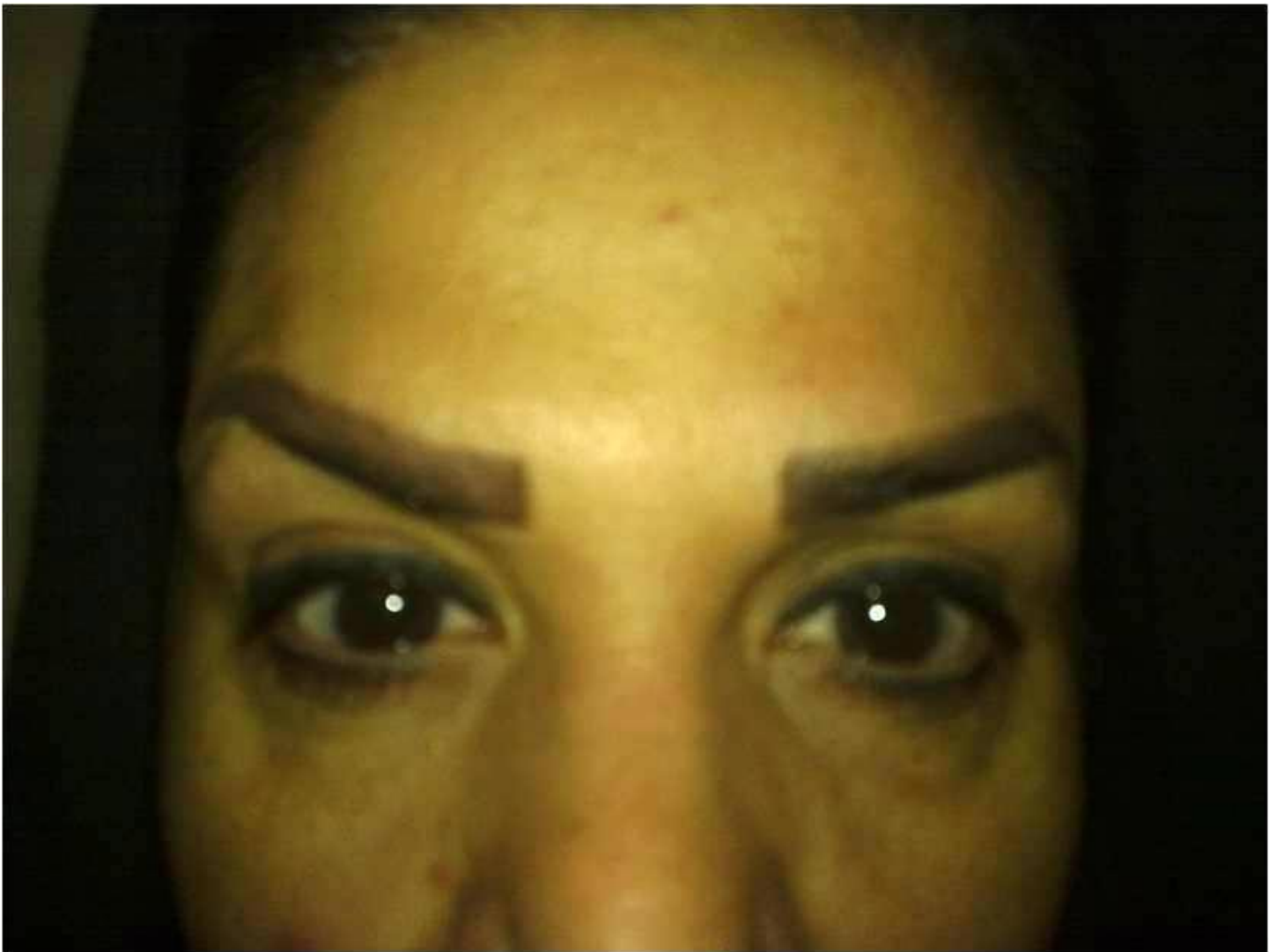
- Apraclonidine 0.5%
- Phenylephrine 2.5%
- Brimonidine 0.1% or 0.2%

Brow Malposition



“Joker face” type of brow arching (Sinister)

Asymmetric result

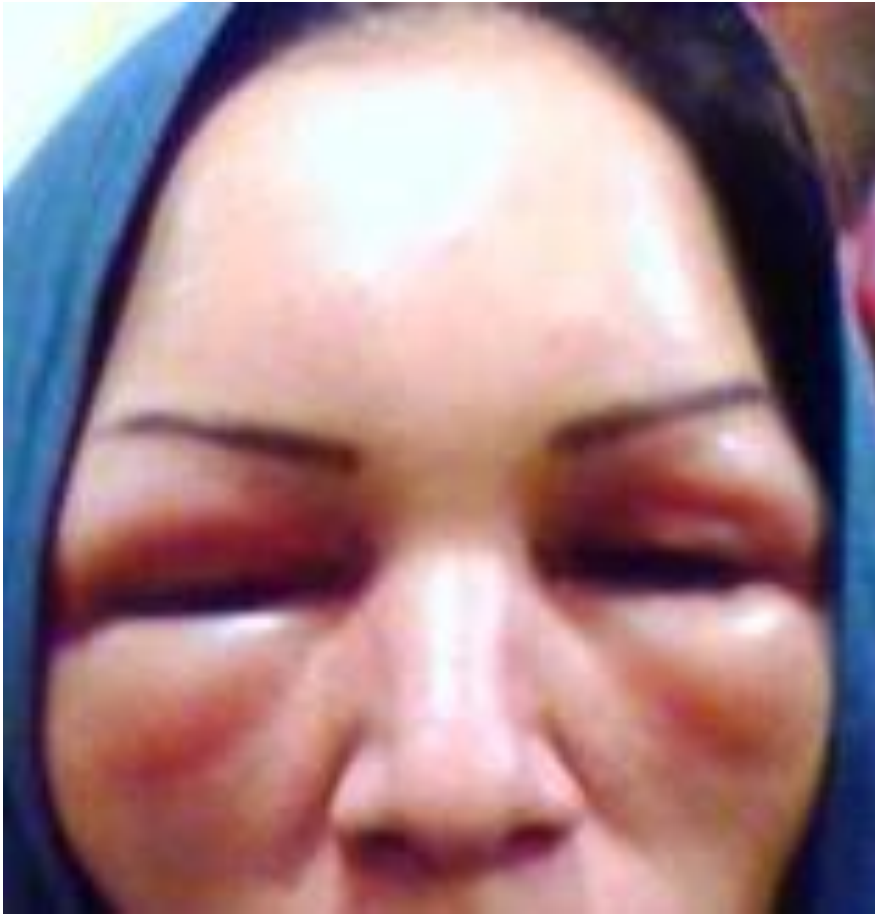

Ectropion

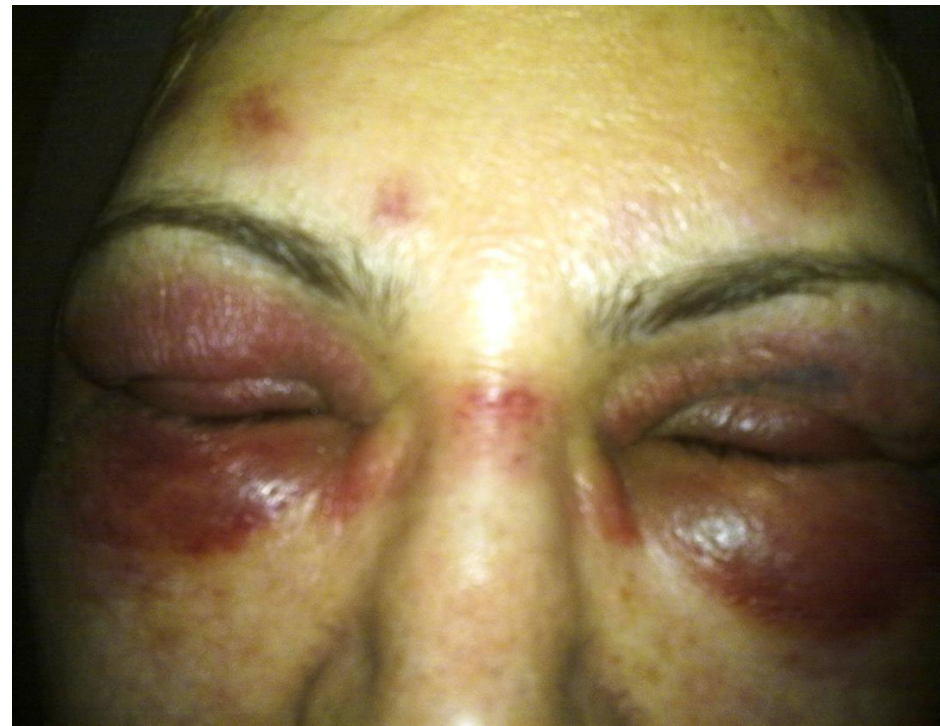Especially in :

- **Older patients**
- **Hx of Lower eyelid Surgery**
- **Lower lid Laxity**

Allergies to Botulinum Toxin-A



Formation of Antibodies



Strabismus

Transient strabismus has been observed

- **Lateral rectus**
- **Inferior Oblique**
- **Medial rectus**
- **Superior Oblique**

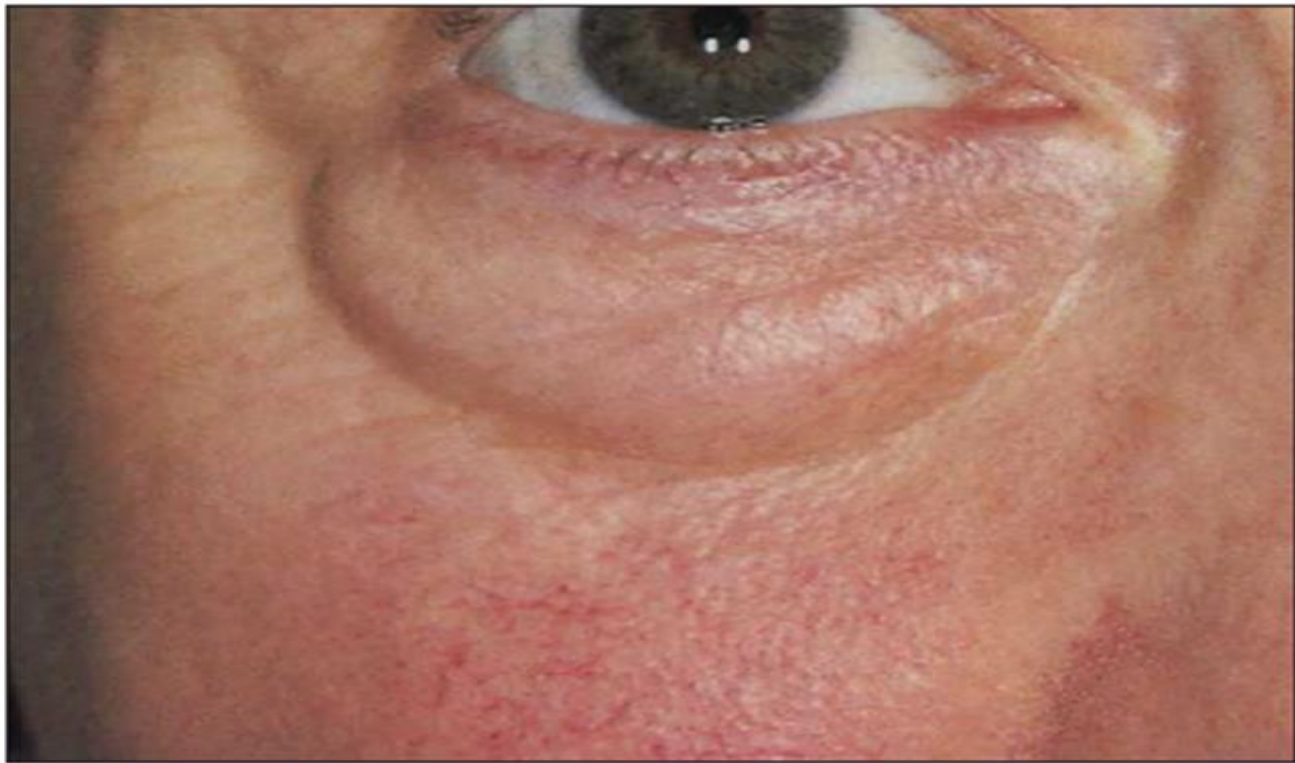
Pseudoherniation of Infraorbital fat pads

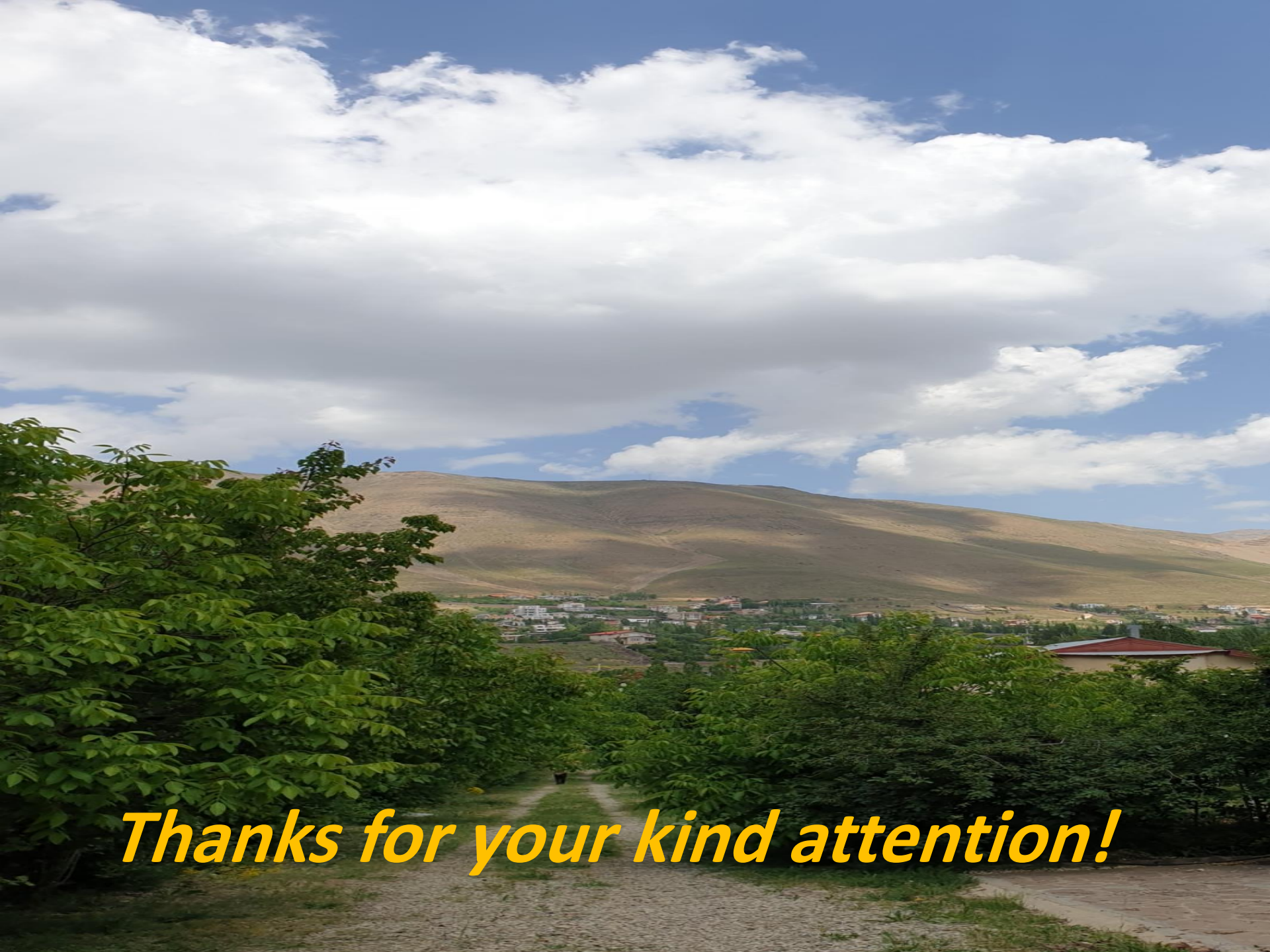In patients with Lax septal support

Best avoided in these patients !

Lower lid bags (dermatochalasis and/or orbital fat)

Avoid injecting botulinum toxin **medial to the outer orbital rim in patients with excessive lower lid skin and fat** as this will cause sagging of the orbicularis muscle with **protrusion of the inferior orbital fat**.





Thanks for your kind attention!

Adverse effects of cosmetic BTA injection
in face

How To Reduce Adverse
Effects or
PATIENT COMPLAINTS?

*Soheyla Jafarpour MD, FICO
Oculofacial Plastic Surgeon*

Most of the AEs are not serious

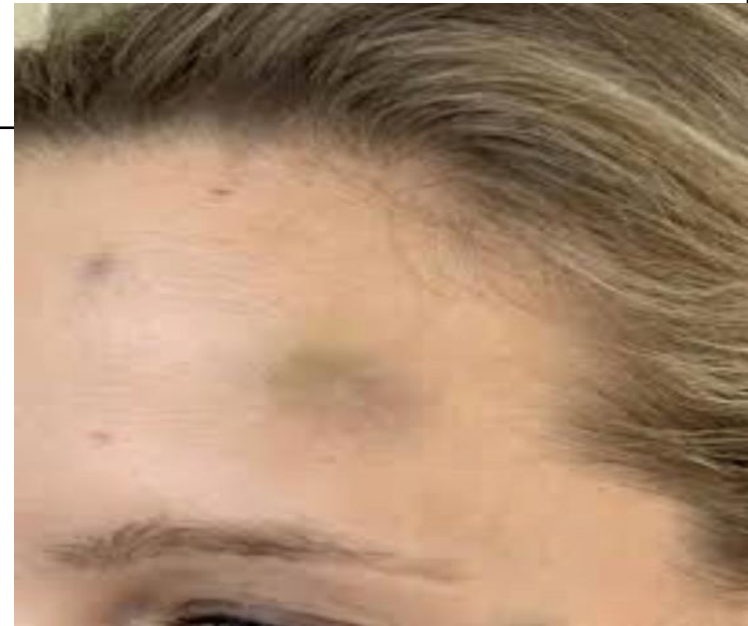- Blepharoptosis :10.9%
- Headache : 4.7%
- Bruise : 2%
- Diplopia : 0.4%
- Asymmetric eyebrow :0.2%

Bruise

- It resulted from the injection rather than the toxin itself.
- Most subjects with bruise happens during first and second years of experience

To decrease the chance:

1. change the needle from 27 to 30 gauge,
2. increase focused illumination (attached to the dentistry chair)
3. stretch the skin to avoid the vessels



Bruising due to damage to intramuscular arterioles is completely unavoidable

Bruising is an inevitable side effect of any intramuscular injection.

Compress the injection site immediately after treatment and apply ice.

Avoid injecting patients taking aspirin, non-steroidal anti-inflammatory preparations or Ginko biloba – a homeopathic inhibitor of platelet function – in order to reduce the risk.

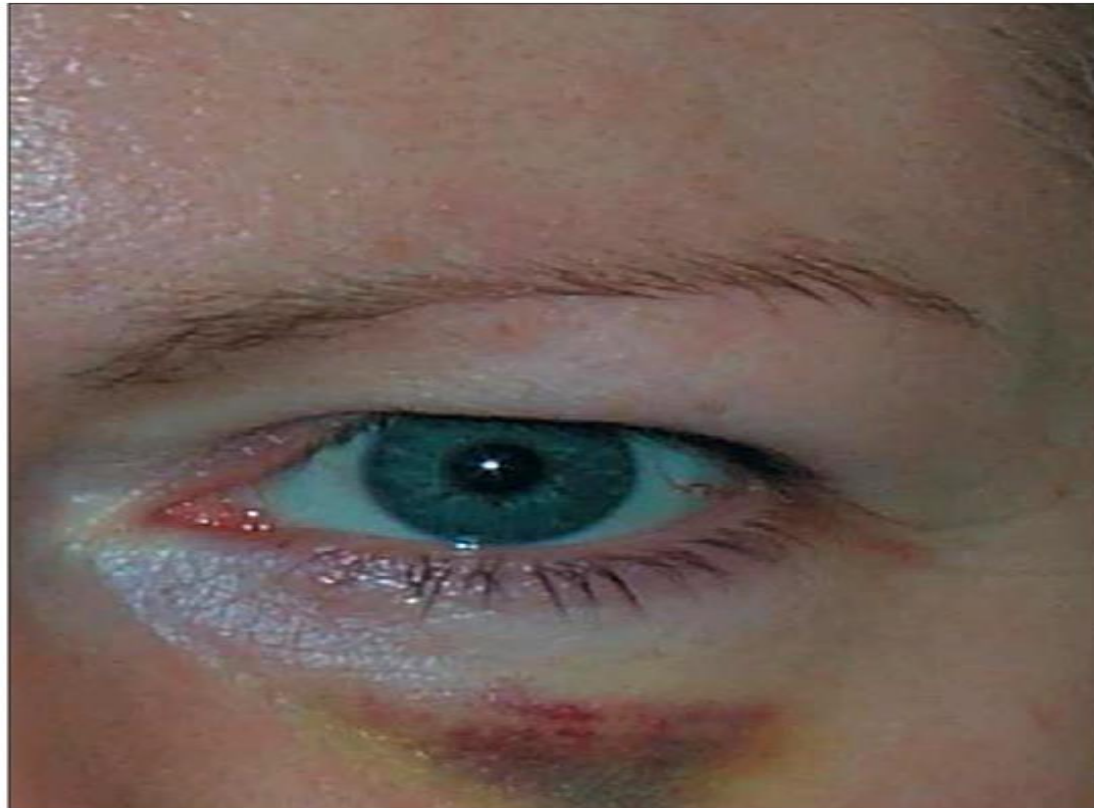
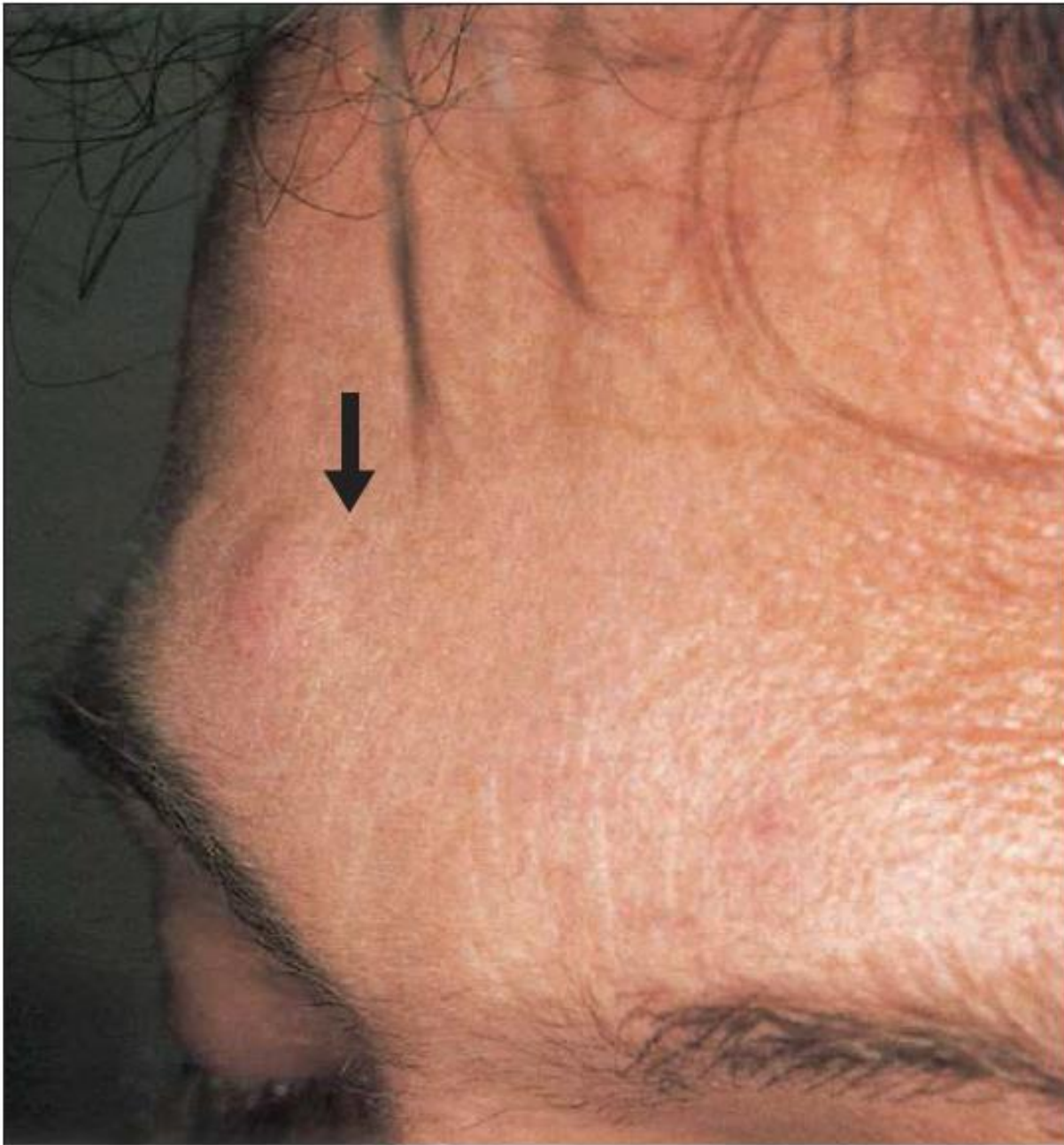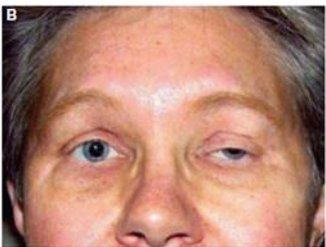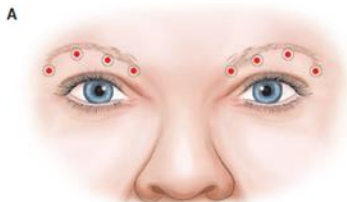




Fig 4.6 Granuloma on forehead at site of Botox® injection (arrow).



Blepharoptosis




Fig. 20-15 A, A diagram demonstrating the diameter of botulinum spread. Injection below the brow should be avoided, because the levator muscle is within the circle of botulinum effect. Injection in this area can cause upper lid ptosis. B, A patient who developed left upper lid ptosis after injection with botulinum.

- Main cause: Diffusion of the toxin up to 3cm
- Resulted from closer injection to the orbital rim.
- The diffusion may result from injection of frown lines and or crow's feet where the toxin can pass through the septum and cause blepharoptosis.
- presence of pre-injection subtle blepharoptosis that has been compensated by the frontalis muscle action → → →
Weakening of the frontalis muscle, uncover the preexisting ptosis.

Complaint: a droopy eyelid

True ptosis following botulinum toxin is due to **inadvertent treatment of the levator palpebrae superioris muscle.**

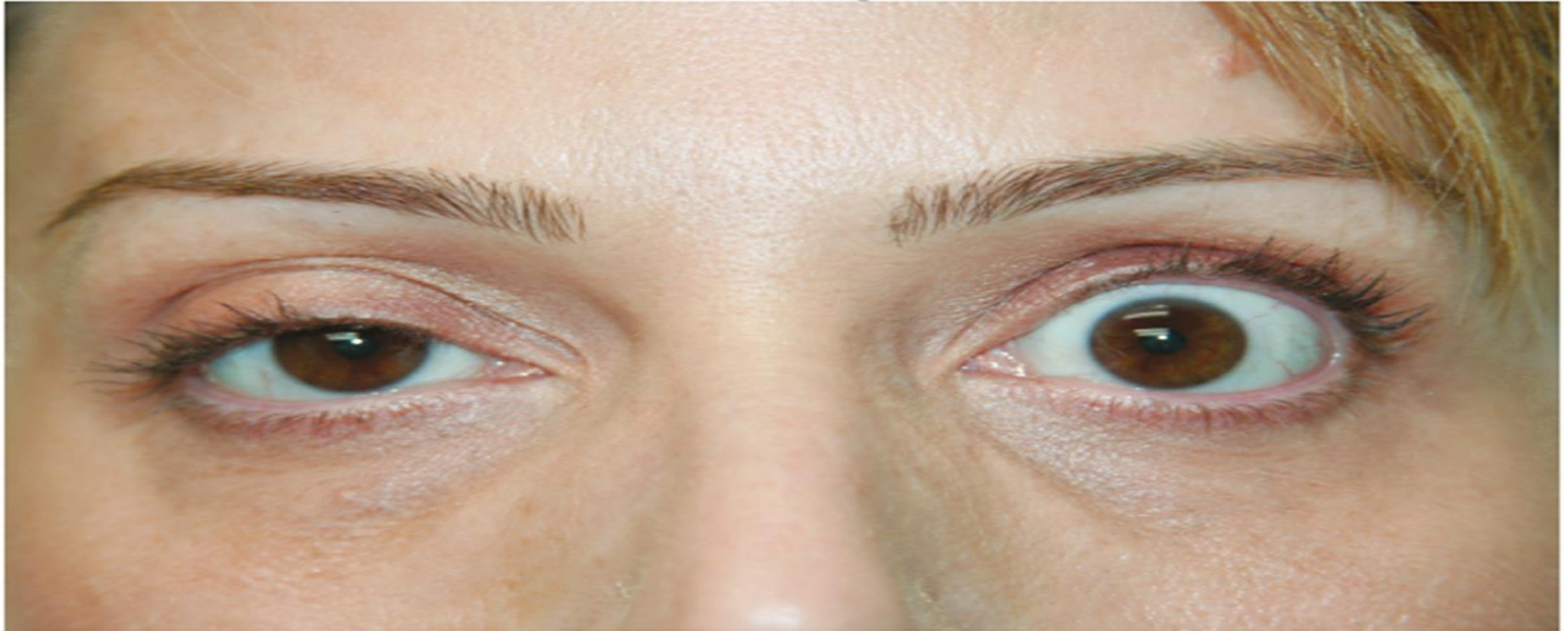

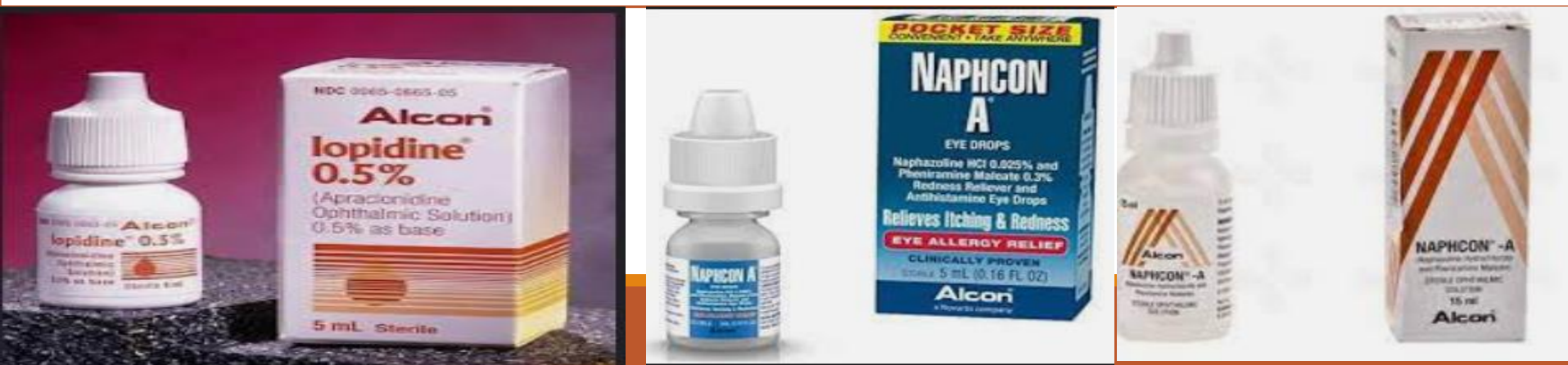Figure 8. Right-sided blepharoptosis three weeks after botulinum toxin treatment of the glabellar complex for frown lines.

Treatment of botulinum-induced ptosis is **reassurance, reminding the patient that it will recover as the BTX wears off**. Recovery is reported to occur between **2 weeks and 3 months**

Stimulation of Müller's muscle with an **α -adrenergic agonist** include the following:

- Naphcon A (**naphazoline and pheniramine**): a nonprescription over-the-counter allergy ophthalmic drop used for allergic ocular symptoms
- Iopidine 0.5% (**apraclonidine**): a prescription drop used to treat glaucoma (Alcon Inc.)

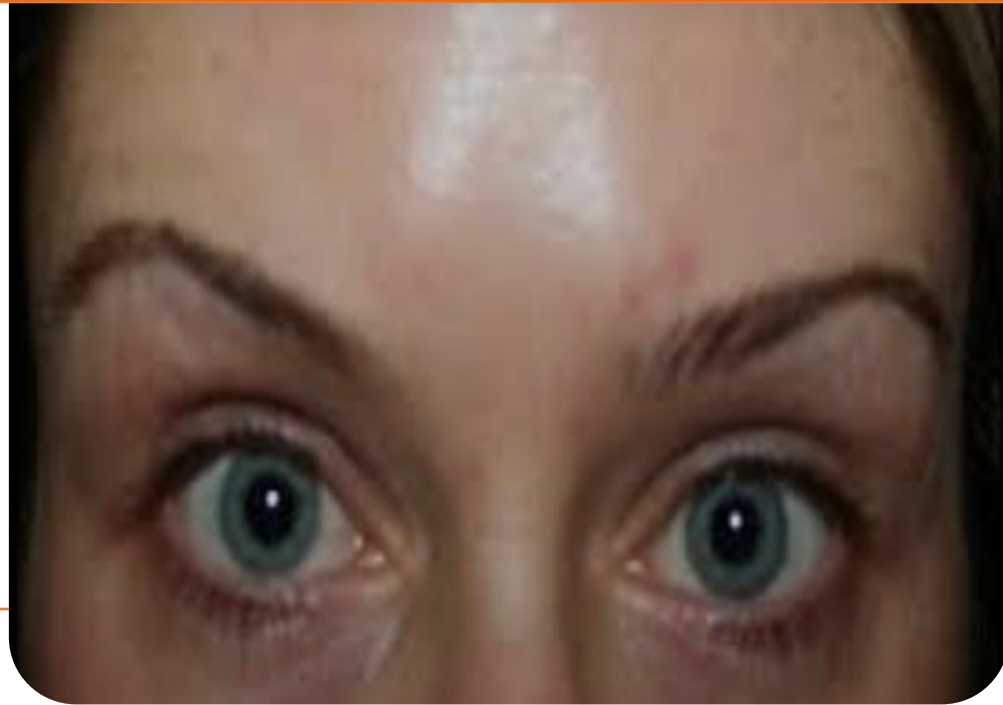Dosing of these drops is titrated by effect; usually 1 to 2 drops can be used **2 to 3 times a day**. Side effects or overuse of the drops may result in blurred vision, dry eye, tearing, and lid edema.



Reducing The Blepharoptosis

- A good pre-injection examination of the facial subunits
- Less amount of concentrated injection
- Fewer numbers of injections
- Keeping the site of injections away from the orbital rims

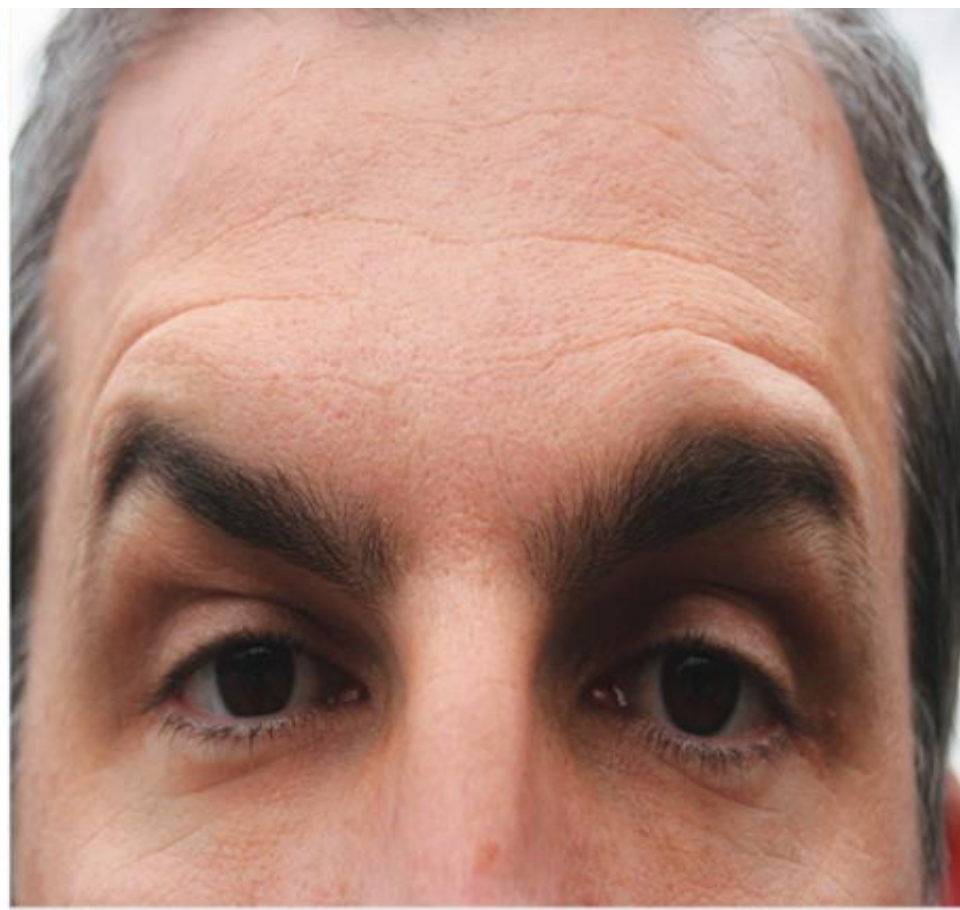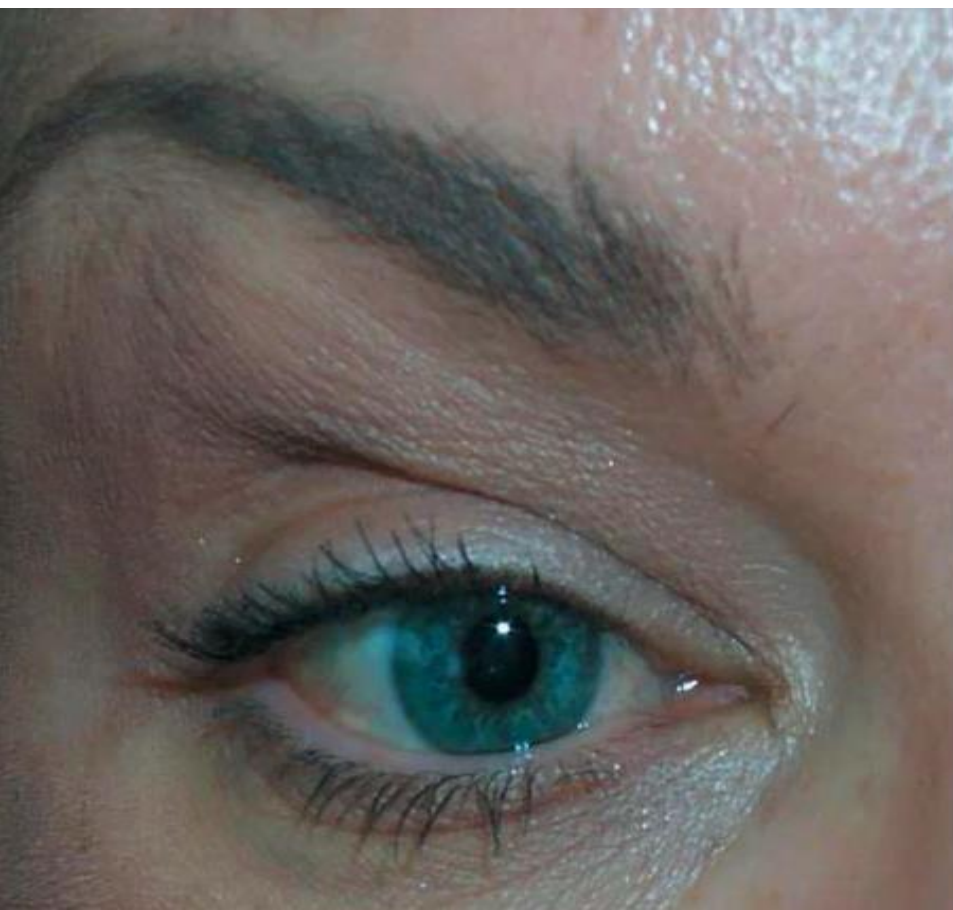Eyebrow Asymmetry



- may result from :
 - 1.a pre-injection asymmetric frontalis muscle action on eyebrow elevation 🖐️ 🖐️ 🖐️ dose could be asymmetrically injected on 2 sides of the face
 - 2.Asymmetric ABO-BTA effect on this area 🖐️ 🖐️ 🖐️ would be corrected on the touch-up session by either raising or dropping the eyebrows

Complaint: peaked eyebrows

The **problem is that residual active frontalis fibers** may sometimes, unpredictably, **distort the shape of the brows.**



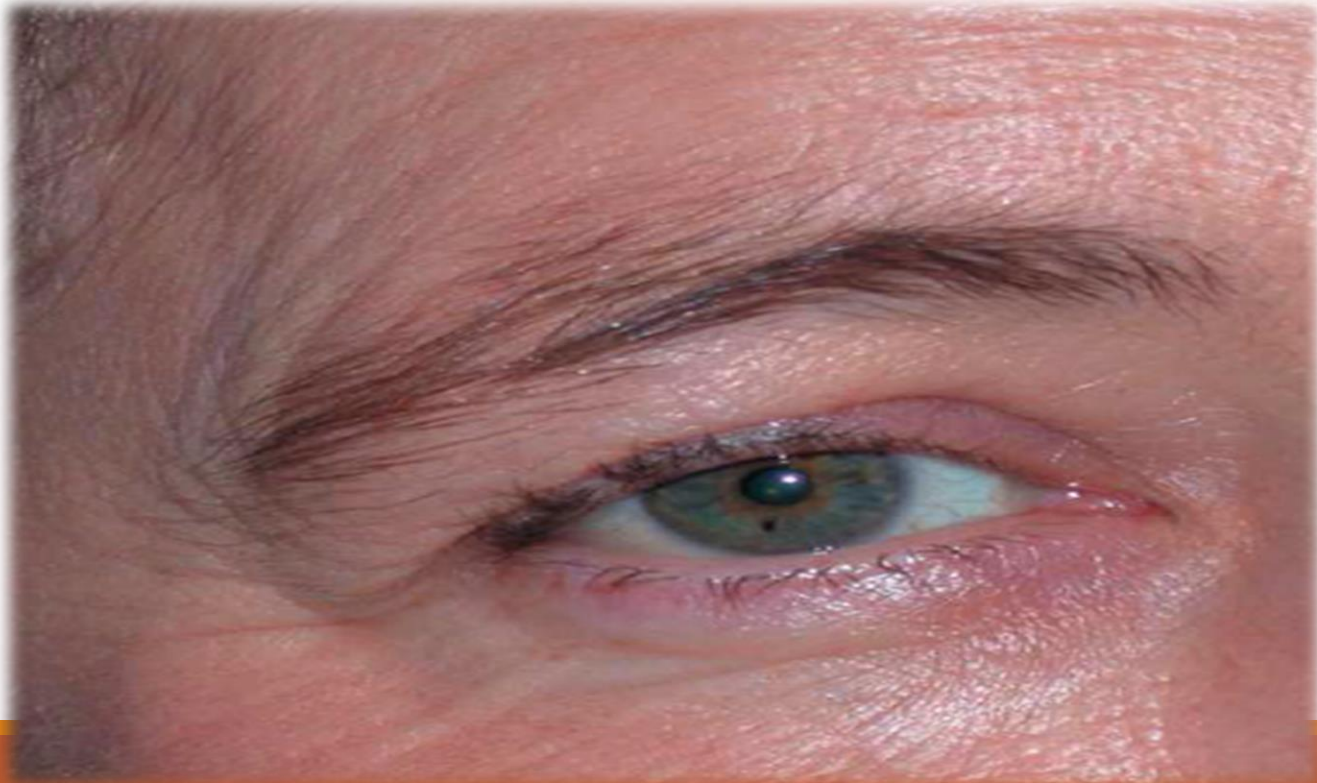peaked eyebrows

an undesirable arched brow (“Spock brow”), which is usually caused by not injecting the lateral point over the brow laterally enough.

If a patient comes with a peaked brow, 2 or 3 units of botulinum toxin should be injected just above the peak of the lateral brow in the frontalis to correct it.

Hooding

Some **crow's feet will persist** despite botulinum toxin. These include the **skin folds at the outer corners of the lids** due either to **brow ptosis** or to **sagging of the temporal frontalis muscle** or both.



Examine the brow–lash distance? If low, regardless of age and skin tone, treatment may cause descension of the medial brow over the orbital rim, causing an unusual ‘tired’ appearance.

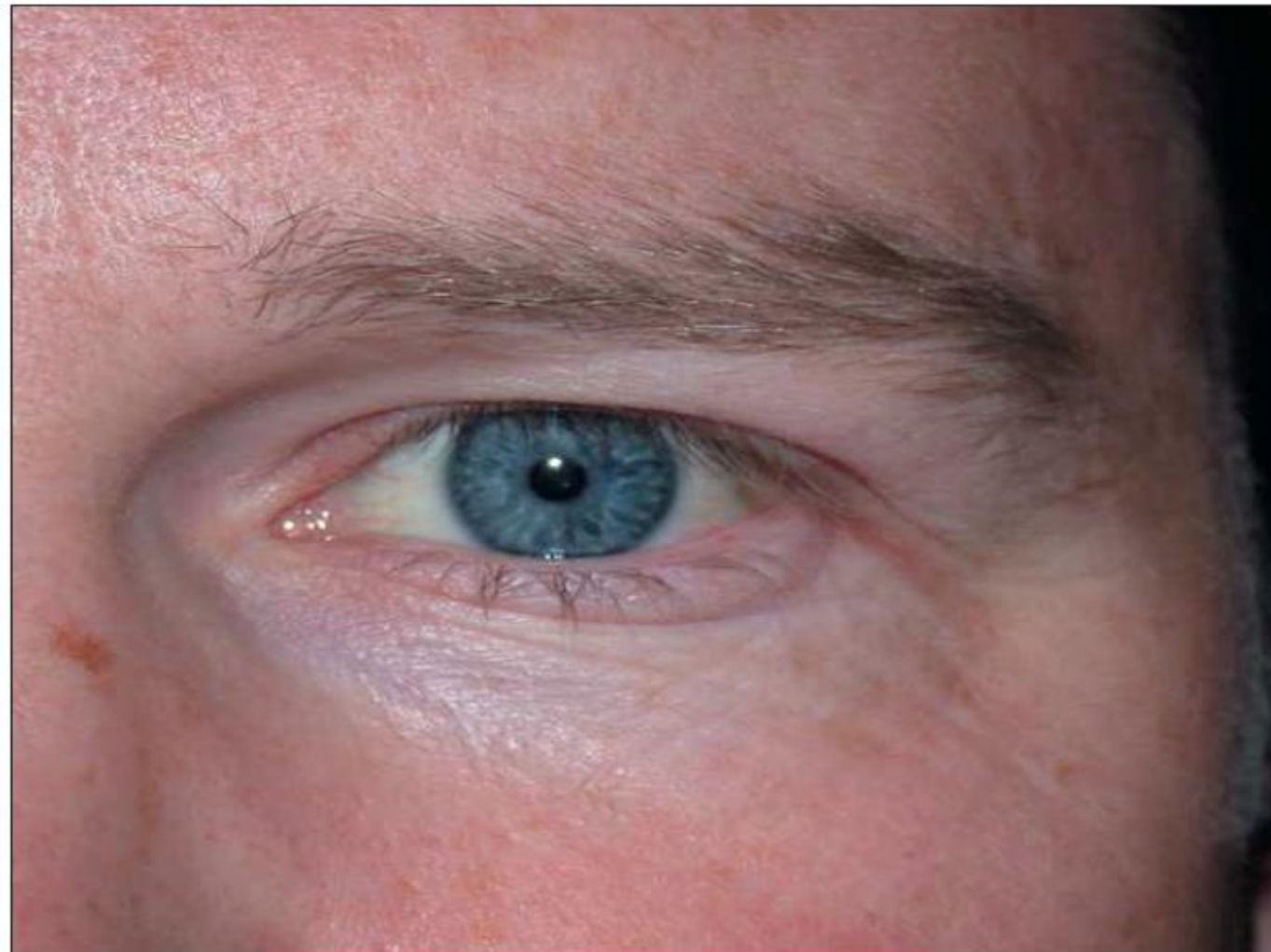

Fig 5.1 Patient with low lash–brow distance.

Headache

- Usually occurs immediately after injection
- Lasts about half a day
- Toxin-related stimulation of muscles immediately after injection
- With a subsequent toxin-mediated relaxation coinciding with headache resolution

Exaggeration of wrinkles

- Due to hyperactivity of untreated muscles
- After injection for forehead lines
- Improves spontaneously.
- Lateral frontalis muscle fibers are responsible for lateral eyebrow elevation that intentionally left un-injected in subjects who seek for eyebrow elevation

Complaint:a watery eye

❖ **Paralysis of the medial pre-tarsal orbicularis** prevents the suction of tears into the lacrimal sac that normally occurs with blinking. It is often seen with Bell's palsy.

It can be **avoided by not injecting botulinum toxin medial to the mid-pupil line.**

❖ Another cause of epiphora is **excessive laxity of the inferior pre-tarsal orbicularis**. The resting tone of the muscle is reduced and so the height of the lower lid drops



Diplopia

Due to diffusion in extraocular muscles,

To prevent:

1. Respect the orbital boundaries

2. and depth of injection in different areas on the upper face

Touch-Up Injection and AE

Although touch-up session corrects any under- or overcorrection of the facial muscles, it simultaneously results in more AE due to more needling and possibly ABO-BTA diffusion.

Age and AE

ABO-BTA cosmetic AE mean age : 41.6 years
AE occurs significantly more in the younger
age group

Eighteen-Point Abobotulinum Toxin A Upper •
Face Rejuvenation: An Eye Plastic Perspective
on 845 Subjects

Mohsen Bahmani Kashkouli, et al.

Resistance

Research suggests that the development of these antibodies is related both to the

1. frequency of administration of BTX and to
 2. its concentration
- 1) Lessen the risk of developing resistance by avoiding booster injections and treatments less than three months apart.
 - 2) Use the smallest dose necessary

Table 1. Contraindications to Botulinum Toxin Injection

Body dysmorphic disorder

Dependency on facial expression for livelihood (e.g., actors, singers)

Dermatoses in the treatment area (e.g., psoriasis, eczema)

Gross motor weakness in the treatment area (e.g., Bell palsy)

Immunocompromised

Infection in the treatment area

Keloidal scarring

Neuromuscular disorder (e.g., amyotrophic lateral sclerosis, myasthenia gravis, Lambert-Eaton syndrome, myopathies)

Pregnancy or breastfeeding

Sensitivity or allergy to constituents of the botulinum toxin product (e.g., cow's milk protein allergy with abobotulinumtoxinA [Dysport])

Unrealistic expectations

TOXICITY

One mouse unit (0.1 ug) is the mean intraperitoneal dose required to kill 50% of a group of 18-20 gram female Swiss-Webster mice (LD-50).

"Estimated" average lethal dose (LD-50) in 70 kg man is 1-2 ug or >2,500 BOTOX units

NO DEATHS have been reported in humans after BOTOX injection

DRUG INTERACTIONS

Aminoglycosides (kanamycin, streptomycin, gentamicin)

Aminoquinolones (chloroquine, hydroxy-chloroquine)

Cyclosporin

D-penicillamine

Nicotinic receptor antagonist blockers (tubocurarine, pancuronium, gallamine)

“ “ agonist blockers (succinyl choline)

Cross reactive antibodies (ALS, Eaton Lambert, Myasthenia Gravis)

Therapeutic Botulinum Toxin

Facial Overactivity

(Blepharospasm, Hemifacial Spasm, ocular Fibrillation,....)

Strabismus

Dry Eye

Lid Retraction

Others

Farid Shekarchian.MD

MUMS

Abnormal movements of the face

. Essential blepharospasm.

Meige's syndrome (orofacial dystonia).

• Breughel's syndrome (oromandibular dystonia).

• Segmental cranial dystonia.

• Reflex or secondary blepharospasm.

• Hemifacial spasm.

• Parkinson 's disease.

• Progressive supranuclear palsy.

• Huntington's chorea.

• Apraxia of eyelid opening (often associated with blepharospasm).

• Drugs.

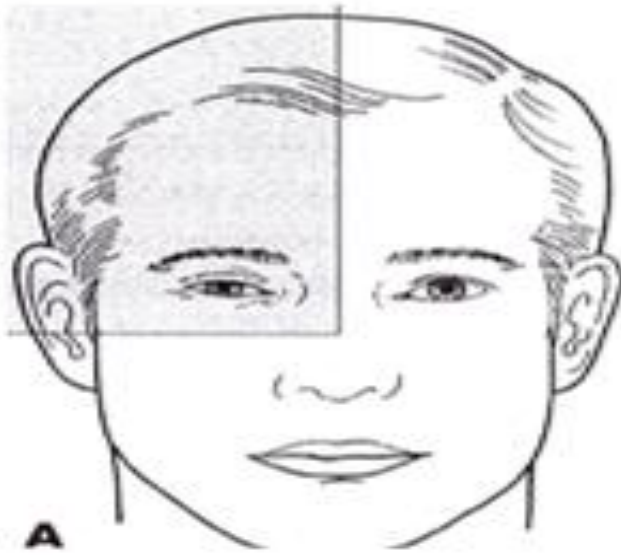
• Tardive dyskinesia.

• Myokymia.

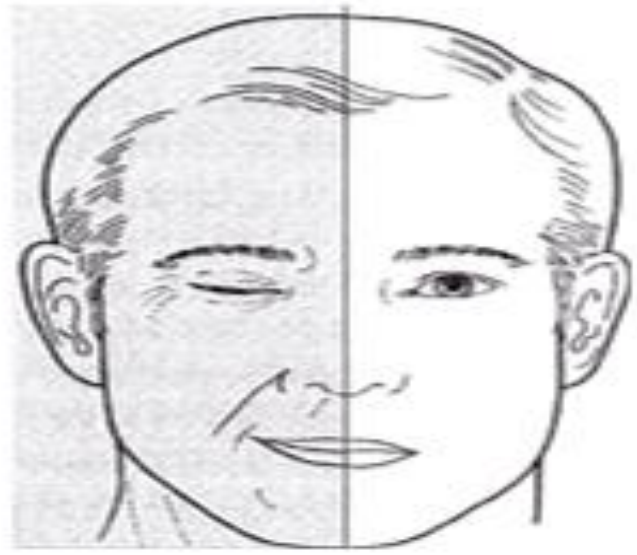
• Aberrant nerve regeneration.

• Habit tics.

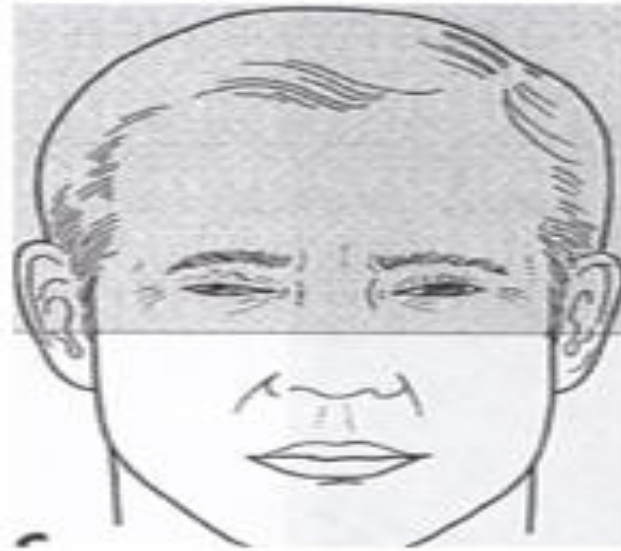
• Tics.



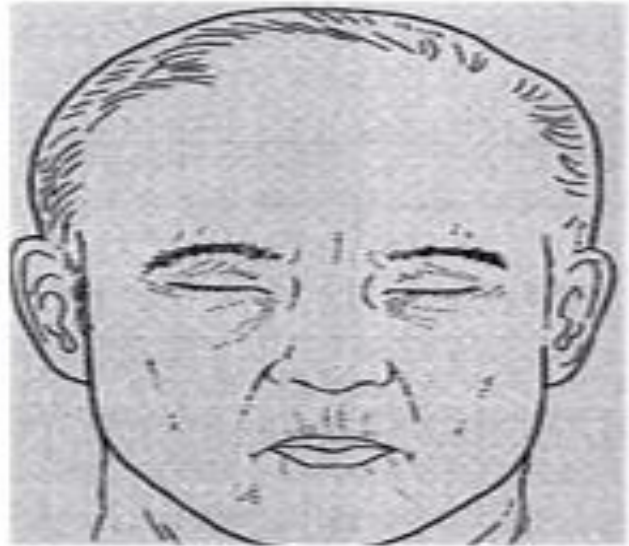A
Orbicularis Myokymia



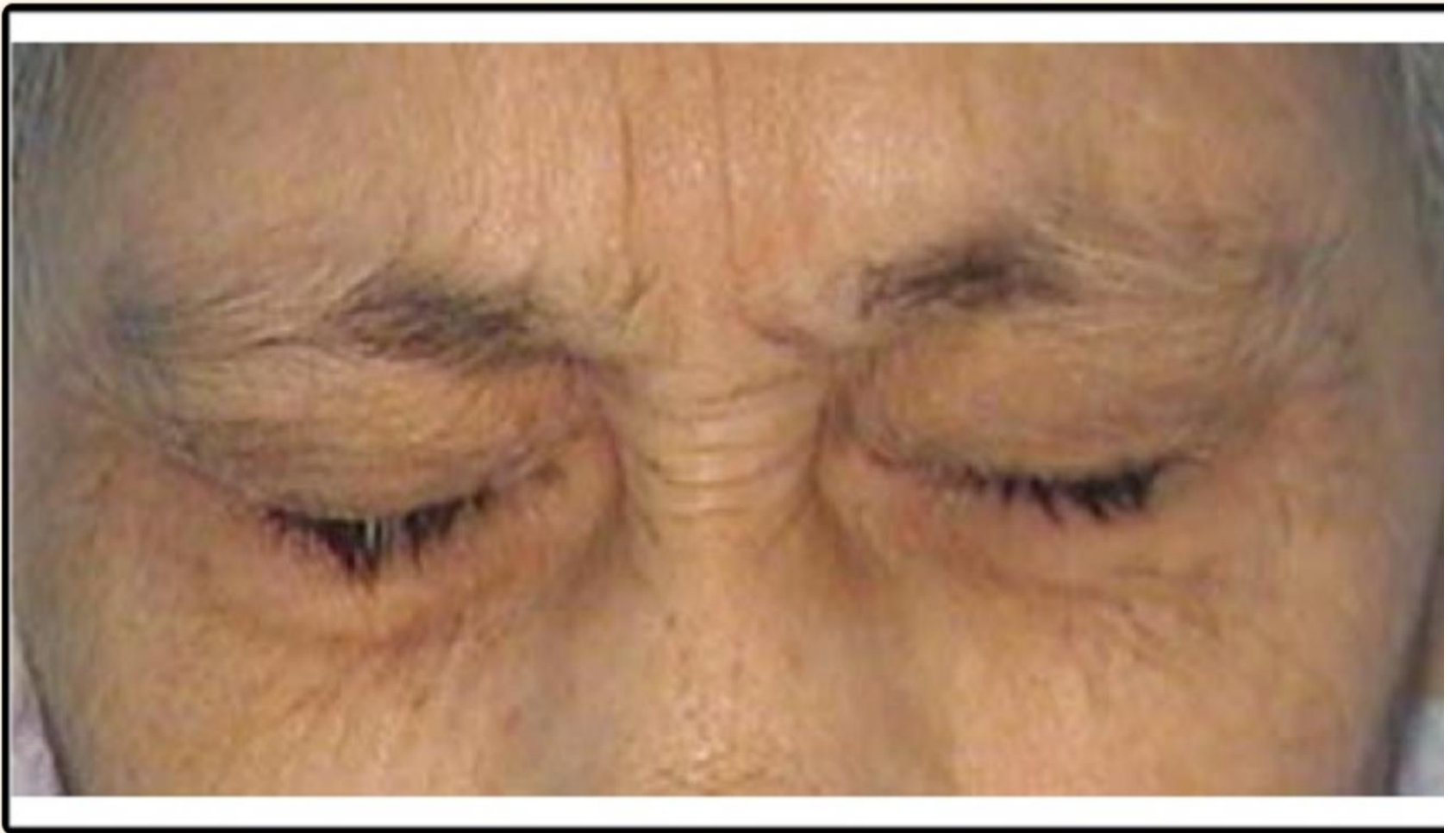Hemifacial Spasm



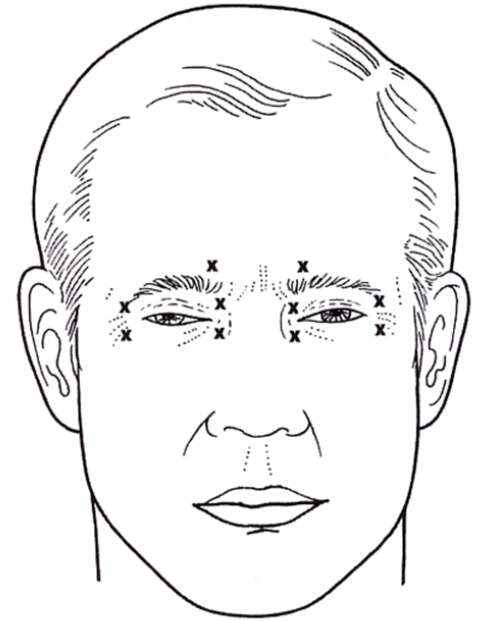
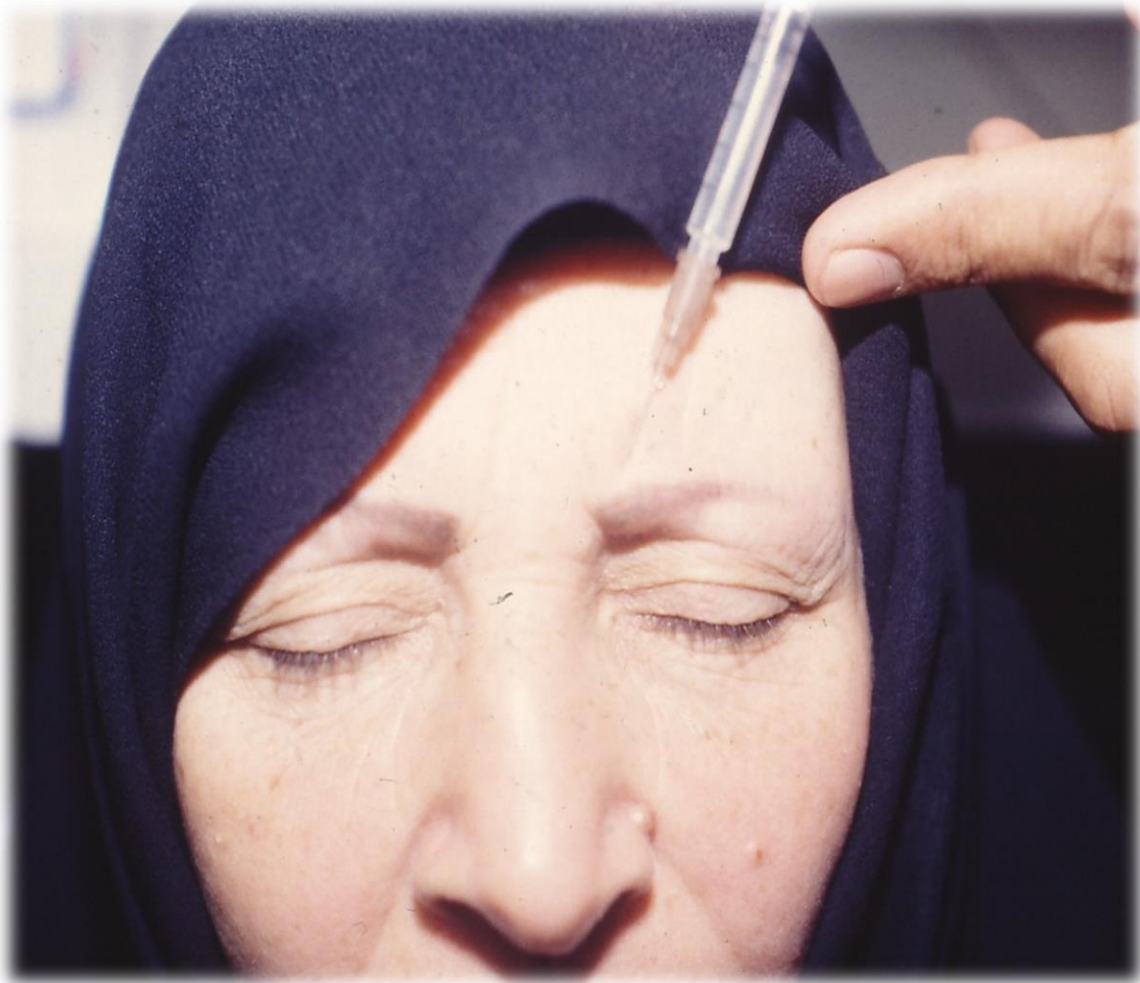Essential Blepharospasm



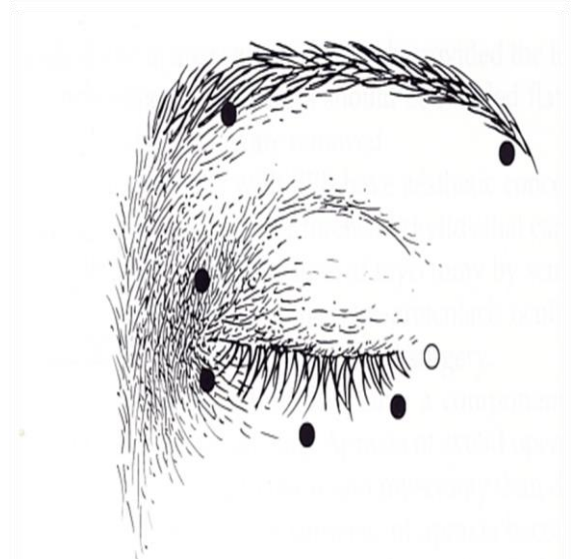
Miego Syndrome



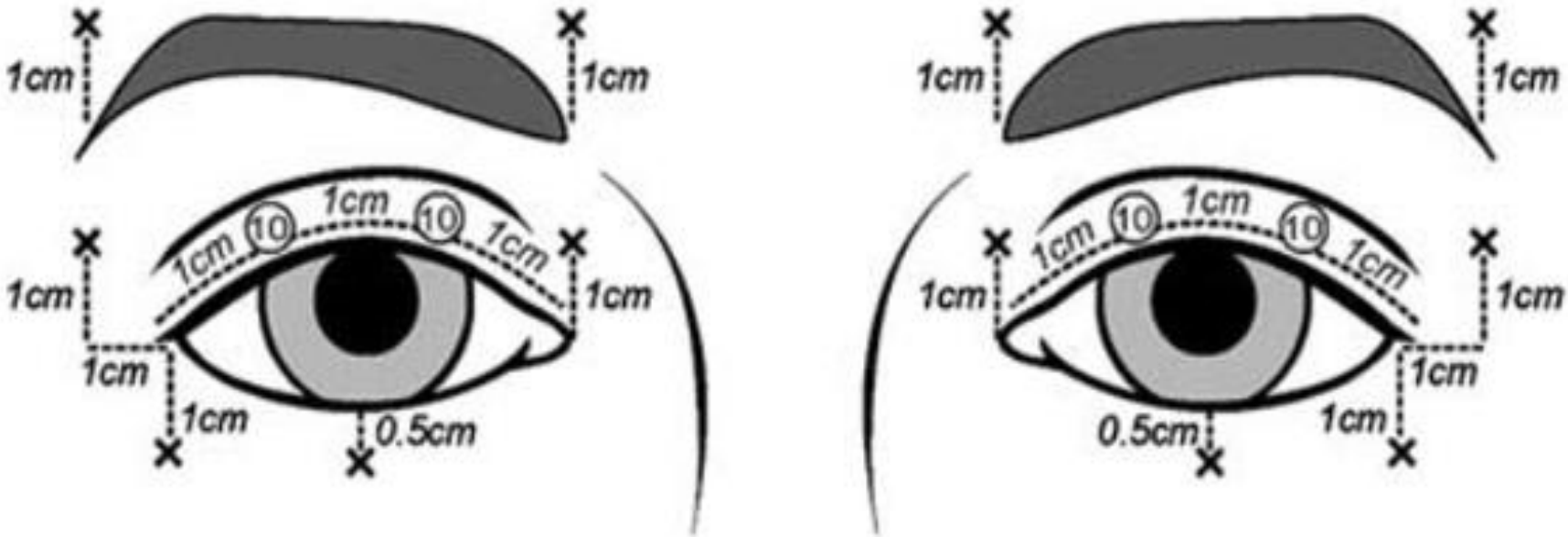
Injection patterns of botulinum toxin type A for benign essential blepharospasm and hemifacial spasm



BTX for Blepharospasm
5 units of Botox per/site
or 15 units of Dysport per/site



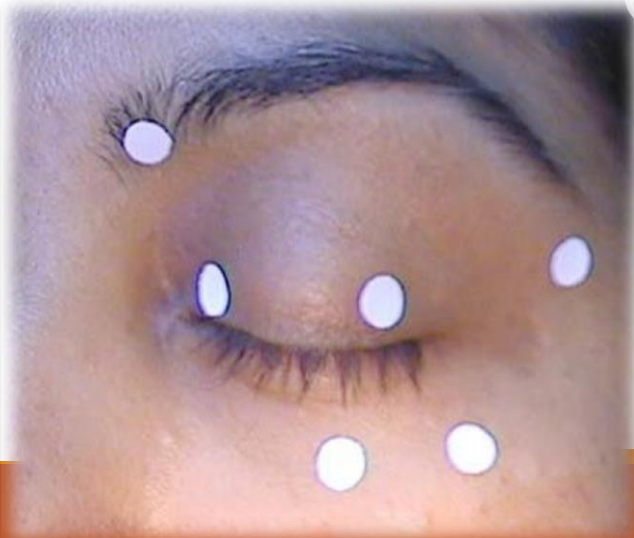benign essential blepharospasm

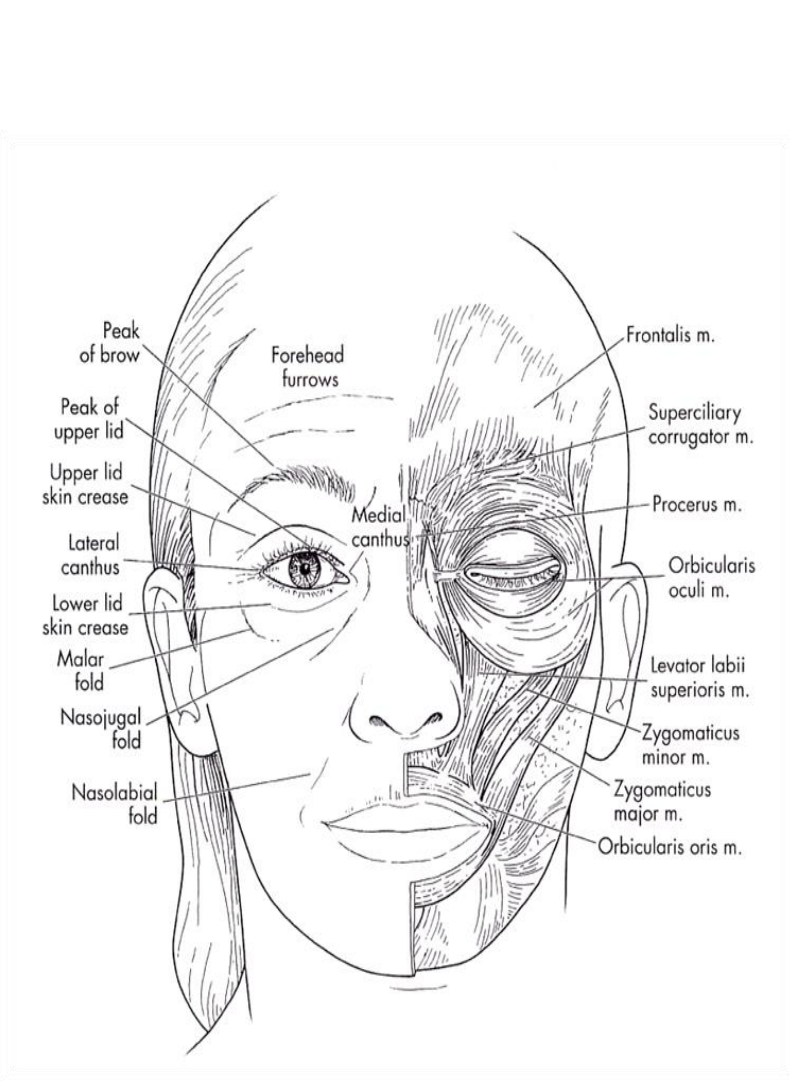
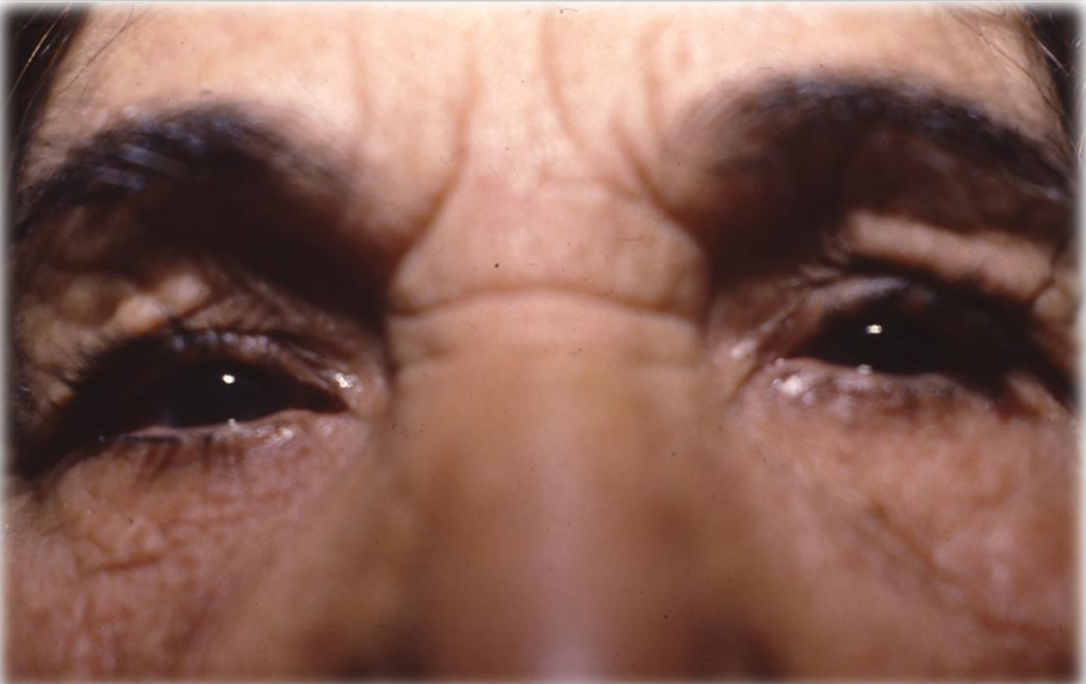
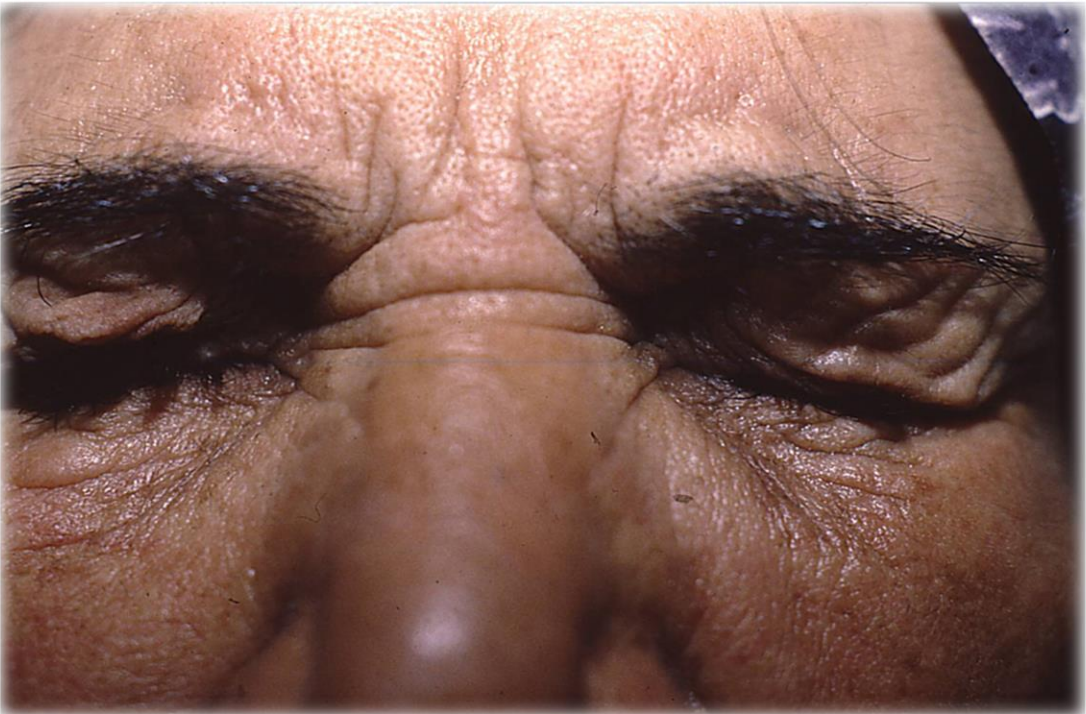
x = 20 units dysport

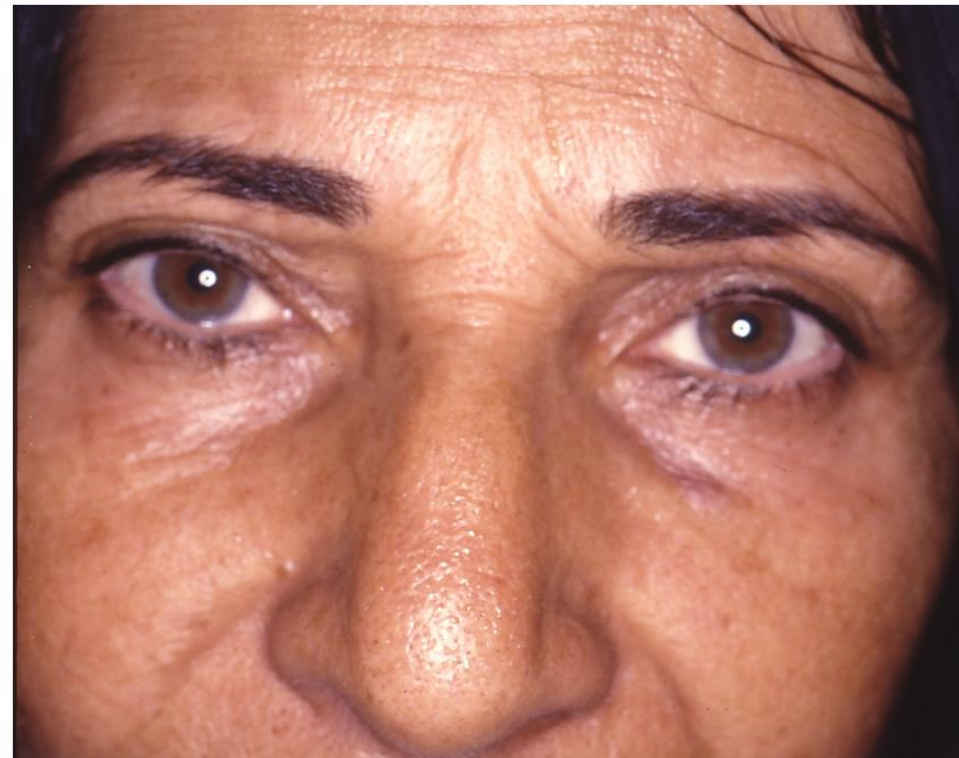
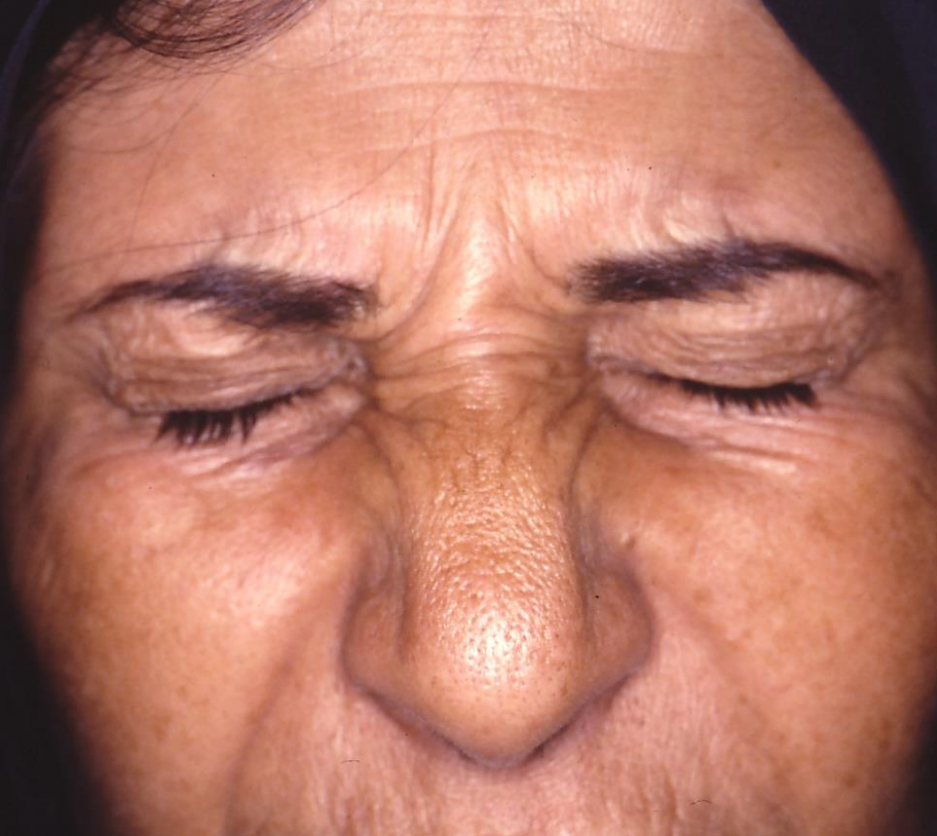

⓪ = 10 units dysport

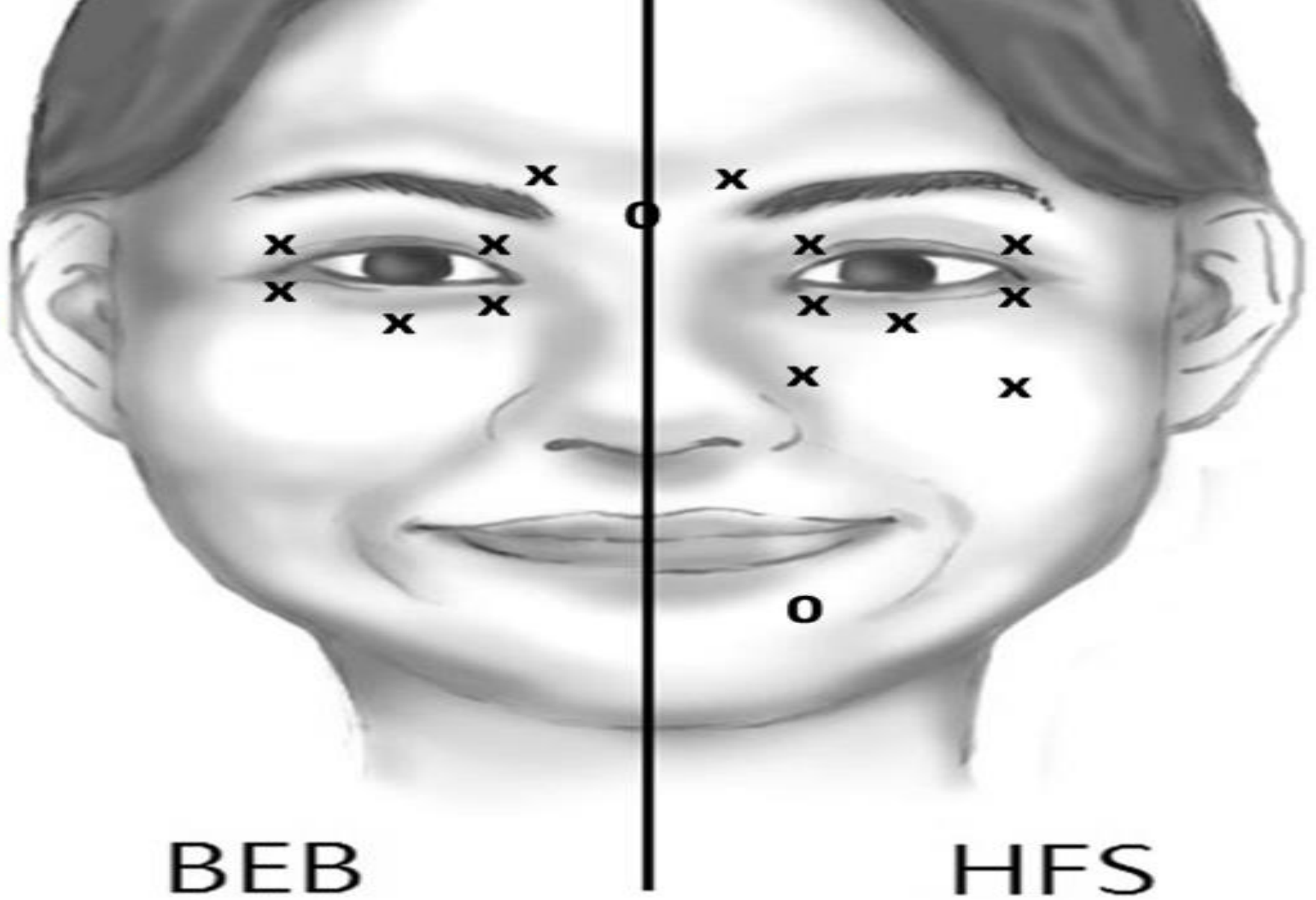
Figure 1 Standard botulinum toxin doses.



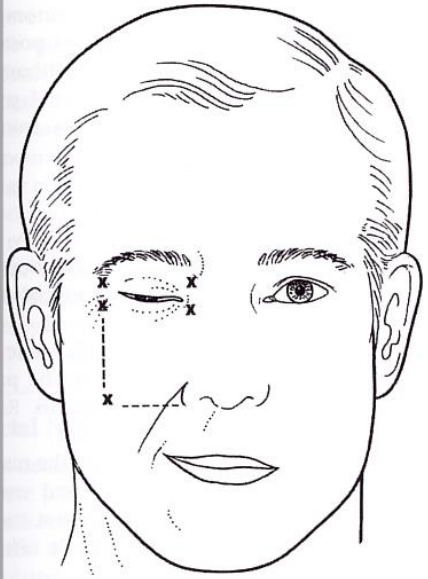
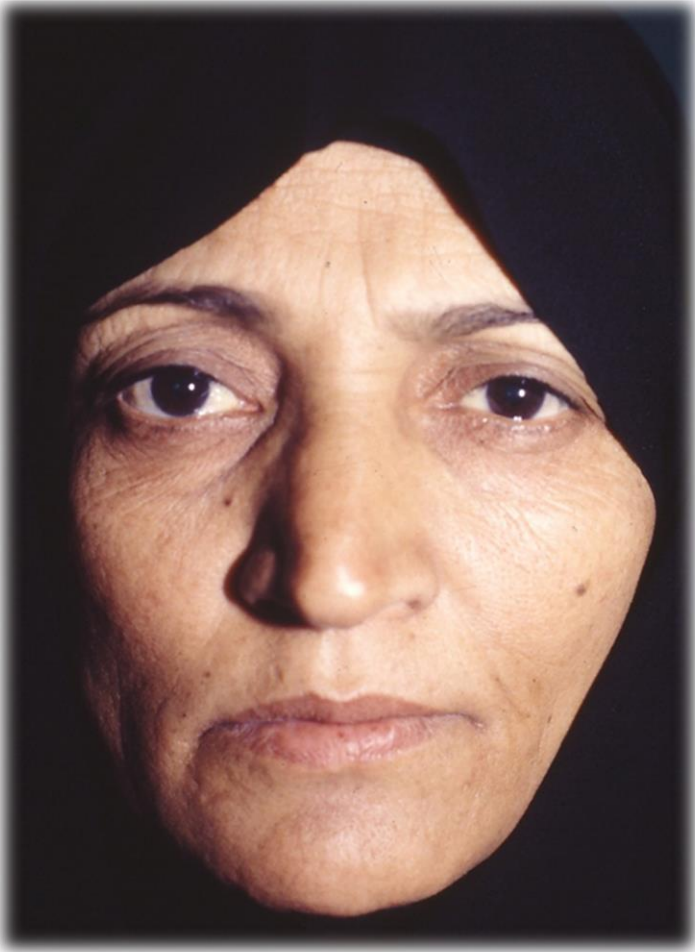
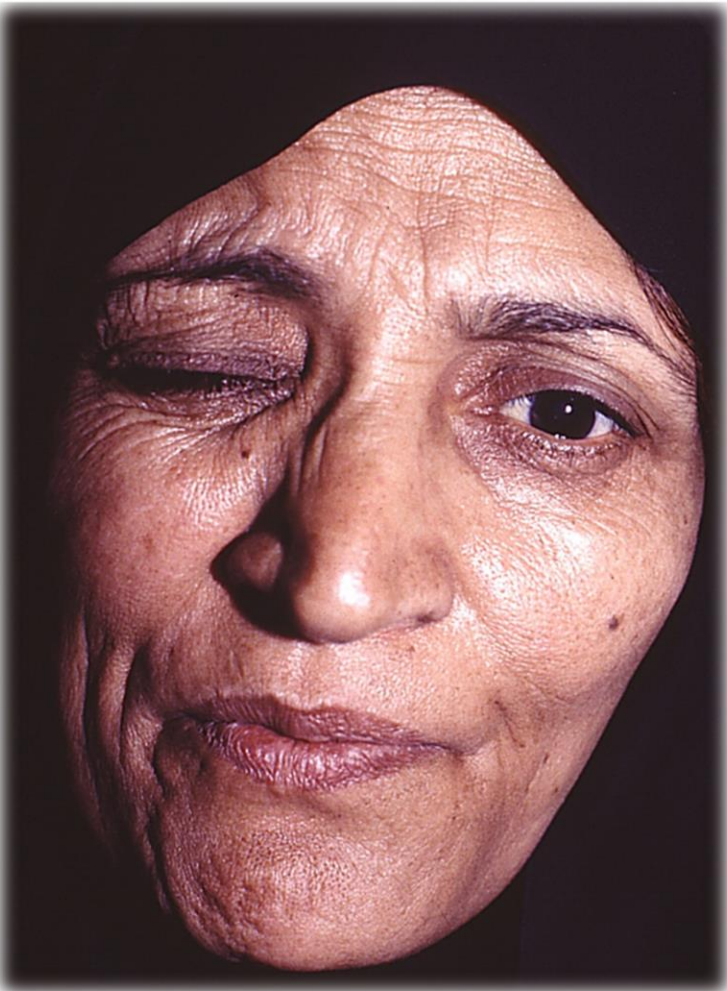
Muscles of facial expressoin





The injection sites scheme for the treatment of benign essential blepharospasm (BEB, left part) and hemifacial spasm (HFS, right part). The dose was 2.5 units per point. For BEB, 12-13 periocular points, 6 on each side with/without 1 procerus muscle, are injected. For HFS, 6-7 periocular points and 2-3 facial points on affected site are injected. 'x' means fixed injection point and 'o' means elective injection point.



BTX for hemifacial spasm
5 units of Botox per/site
or 15 units of Dysport per/site

Patients with **facial hemispasm** frequently require botulinum toxin to a **focus of spasm over the elevator of the lip.**

This **leads to a depression of the corner of the mouth and drooling of saliva** but patients would usually rather have an embarrassing dribble than an uncomfortable spasm and twitching of the side of their face.

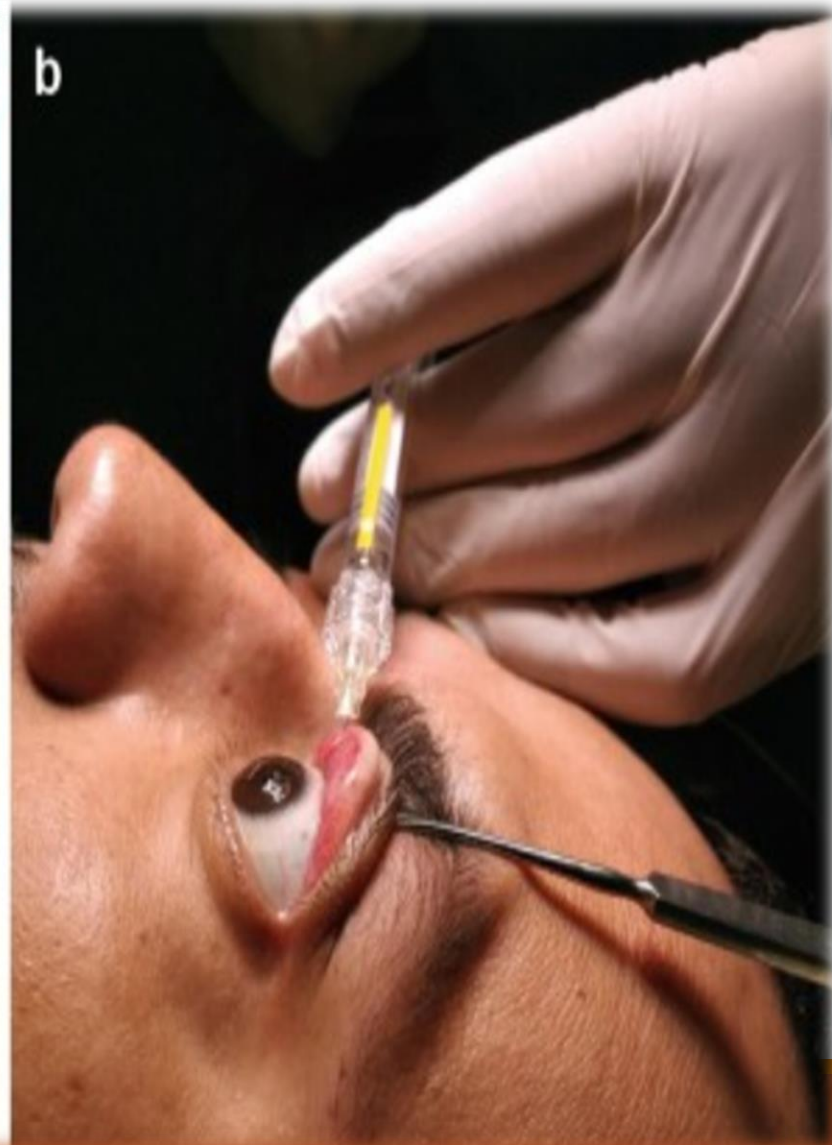
However this complication **MUST** be avoided in a cosmetic practice.

Caution must be used to avoid neurotoxin diffusion into the levator labii alaeque nasi and the levator labii superioris muscles to prevent upper lip droop

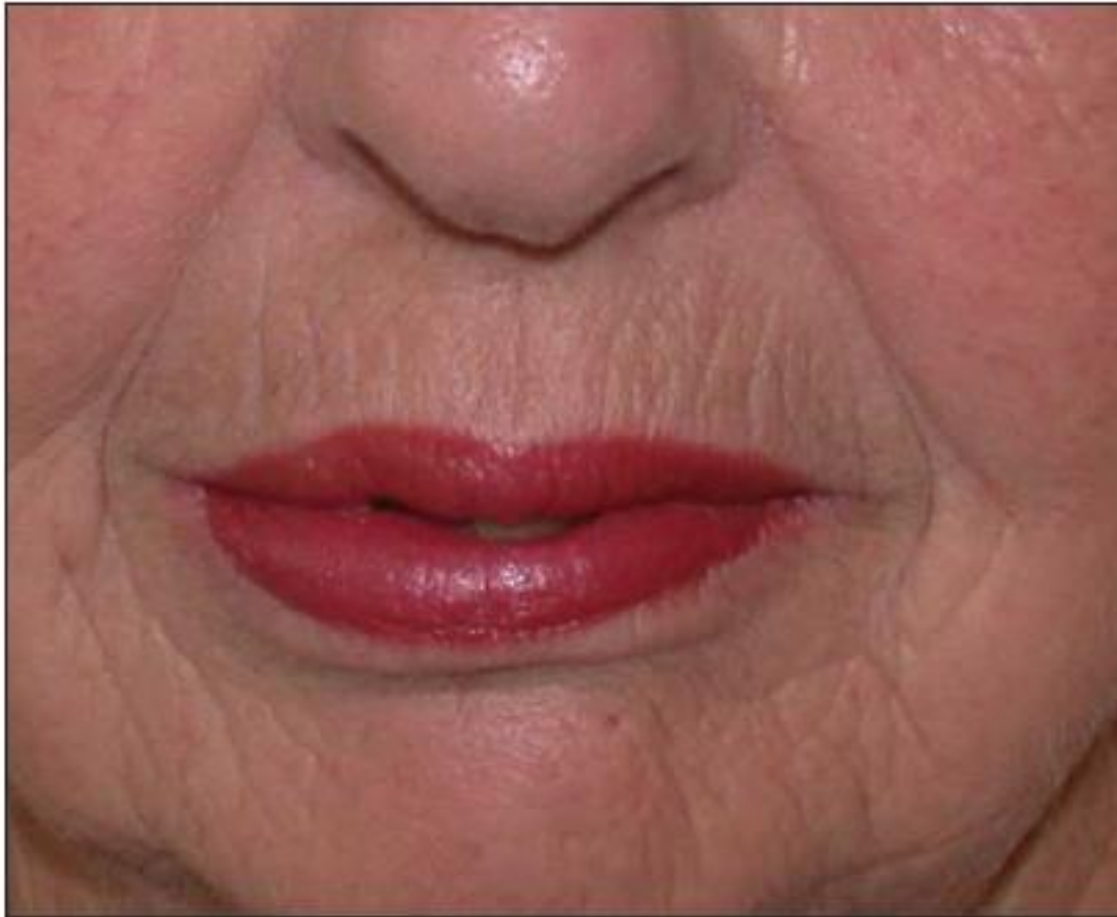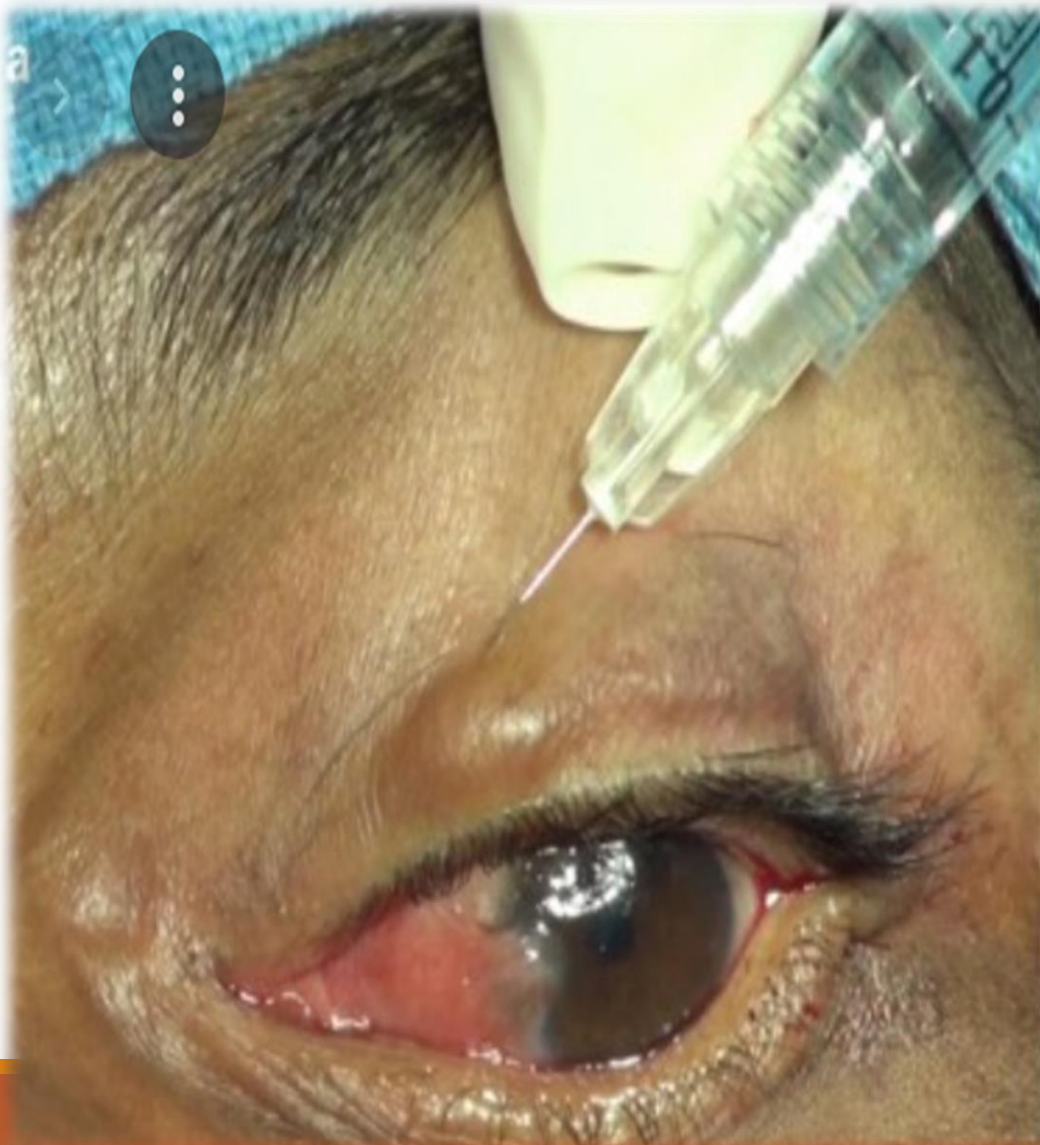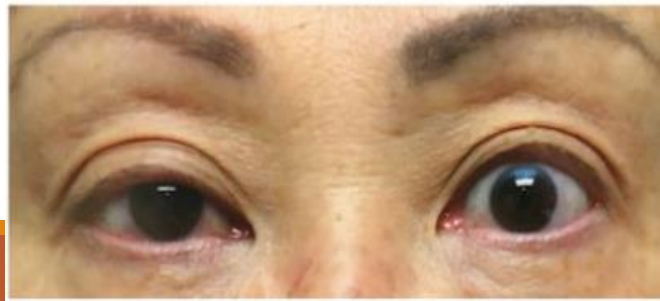


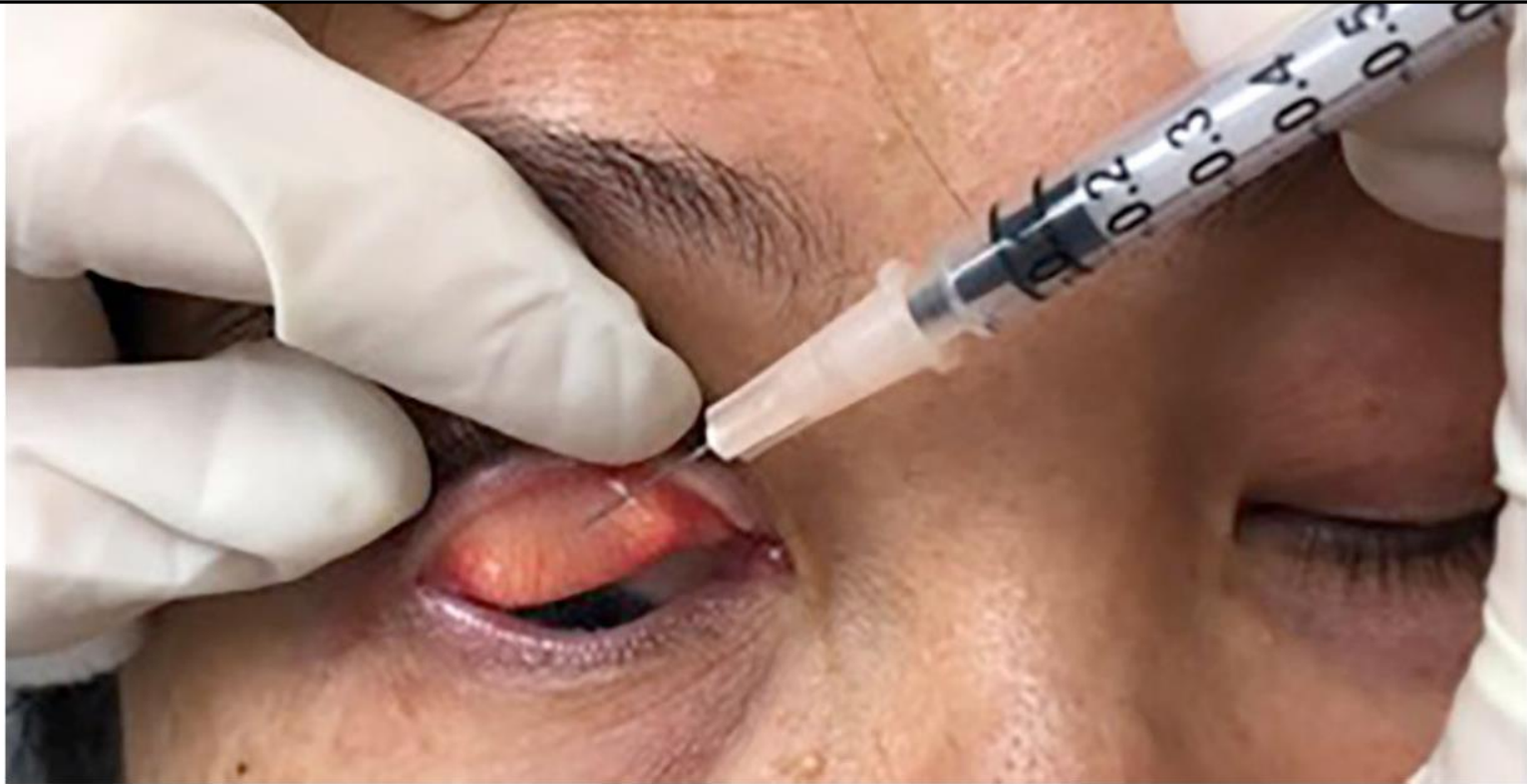Fig 9.2 Mouth droop following botulinum toxin for severe blepharospasm.

Lid Retraction Thx



The upper lid was everted and a single transconjunctival injection was administered at the central upper lid area within 3mm above the superior tarsal border



Chemodenervation Using Botulinum Toxin in **strabismus**

- I. **Paralysis** of the injected EOM **begins within 2–4 days** of injection and lasts clinically for **at least 5–8 weeks**.
- II. A **pharmacologic recession**: the EOM lengthens while it is paralyzed by botulinum toxin, and its antagonist contracts
- III. When used to treat patients with strabismus, the toxin is **injected directly**, with a small-gauge needle, into selected EOMs

Indications, Techniques, and Results

Clinical trials using botulinum toxin for the treatment of strabismus have shown this agent to be **most effective** in the following conditions:

1. **Small- to moderate-angle** esotropia and exotropia ($<40\Delta$)
2. **Postoperative residual** strabismus (**2–8 weeks** following surgery or later)
3. **Acute paralytic** strabismus (especially **sixth nerve palsy**; sometimes fourth nerve palsy), to eliminate diplopia while the palsy resolves
4. **Active thyroid eye disease** (Graves disease) or inflamed or pre-phthisical eyes, when surgery is inappropriate
5. As a **supplement** to medial rectus muscle **recession** for large-angle infantile esotropia or lateral rectus muscle recession for large-angle exotropia

Botulinum toxin injection is usually **not effective** in patients with

1. **large** deviations,
2. **restrictive or mechanical** strabismus (trauma, chronic thyroid eye disease), or
3. **secondary strabismus** wherein a muscle has been overly recessed.
4. **A and V** patterns,
5. **DVDs**, and
6. **chronic paralytic** strabismus.

Complications

Most common adverse effects of ocular botulinum toxin treatment are

- 1.ptosis,
- 2.lagophthalmos,
- 3.dry eye, and
- 4.induced vertical strabismus after horizontal muscle injection.

These complications are usually temporary, **resolving after several weeks.**

Rare complications include

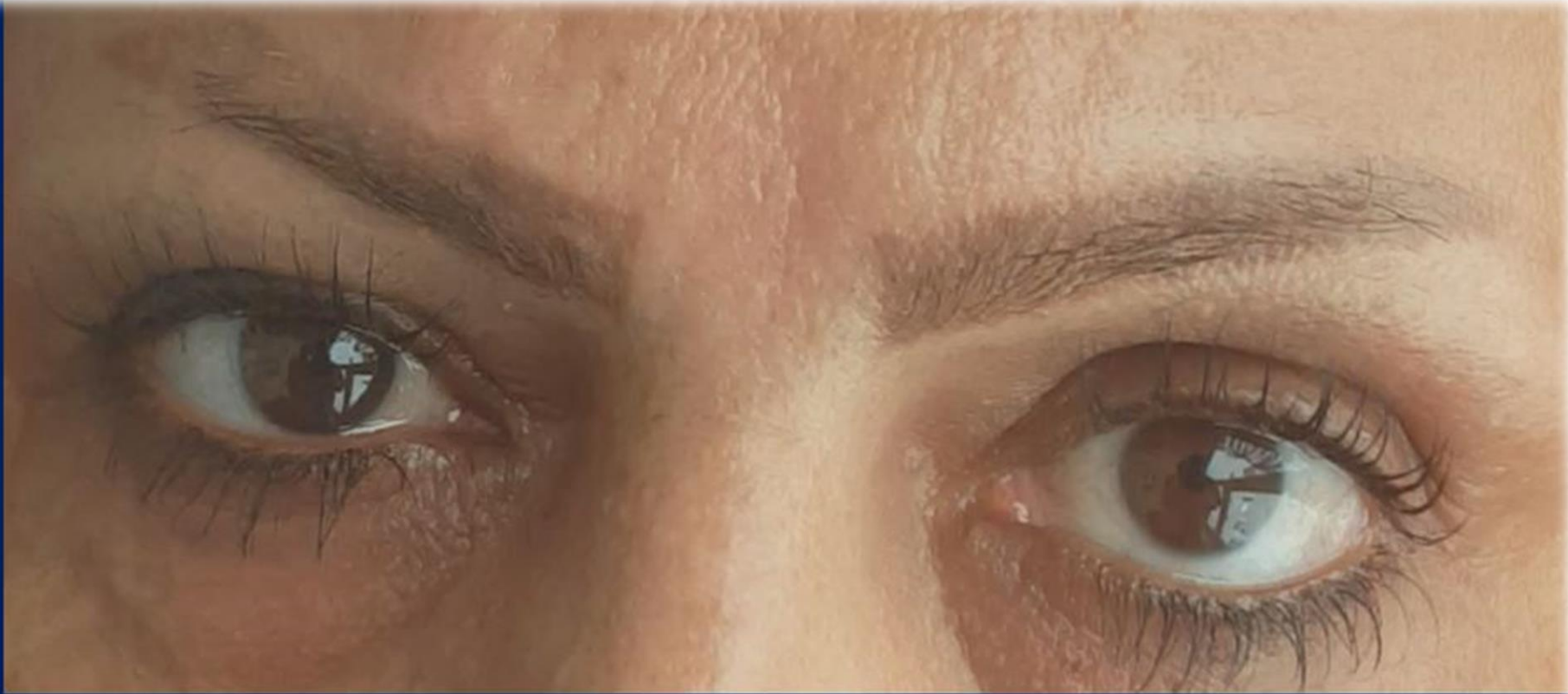- 1.scleral perforation,
- 2.retrobulbar hemorrhage,
- 3.pupillary dilation, and
- 4.permanent diplopia

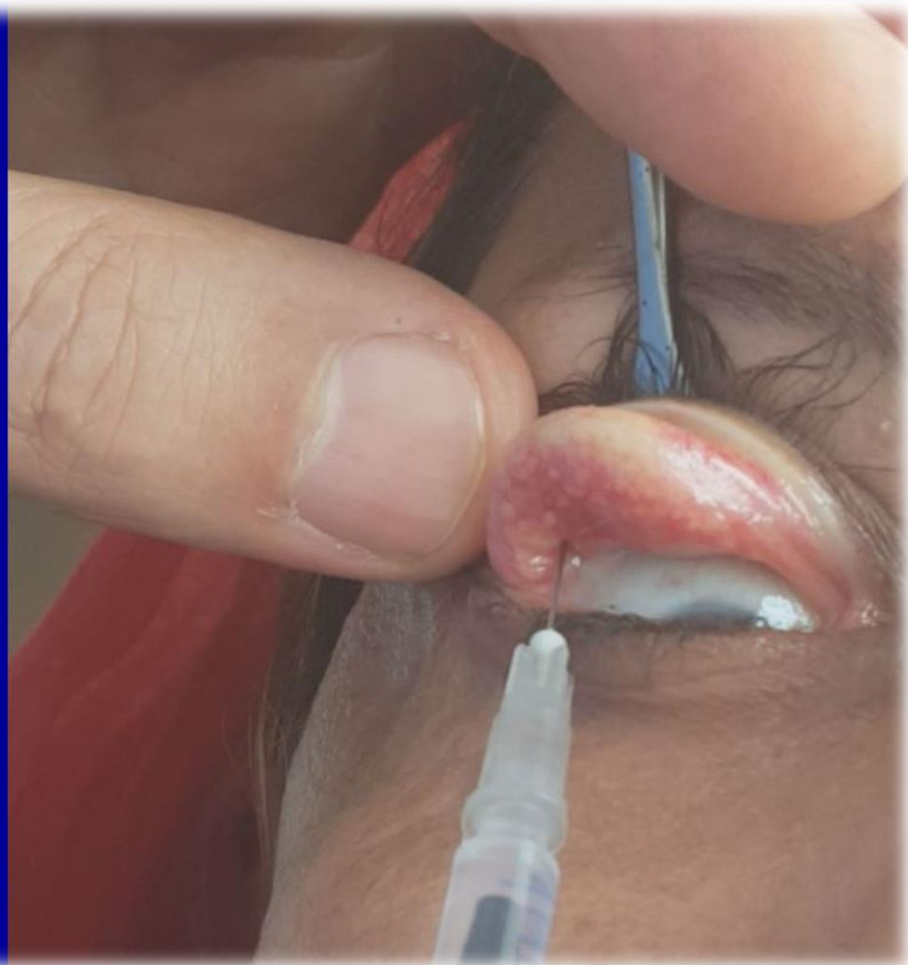
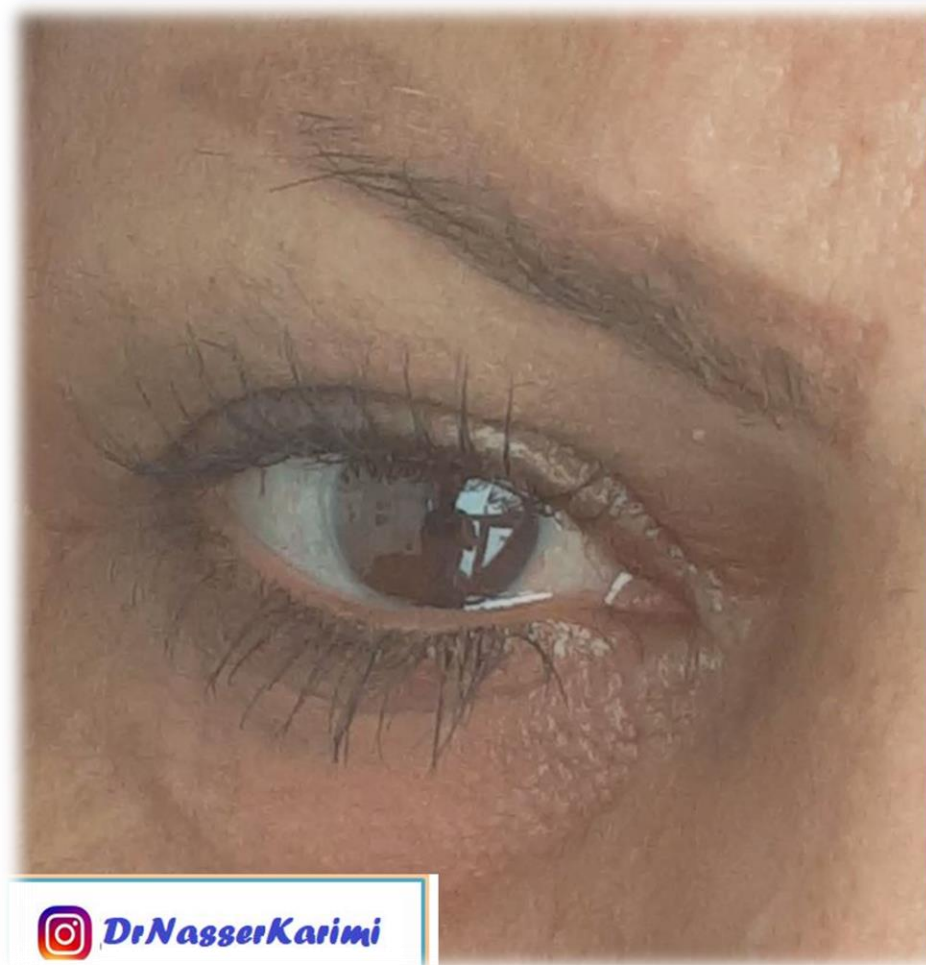
THANKS FOR YOUR ATTENTION

Case Presentation

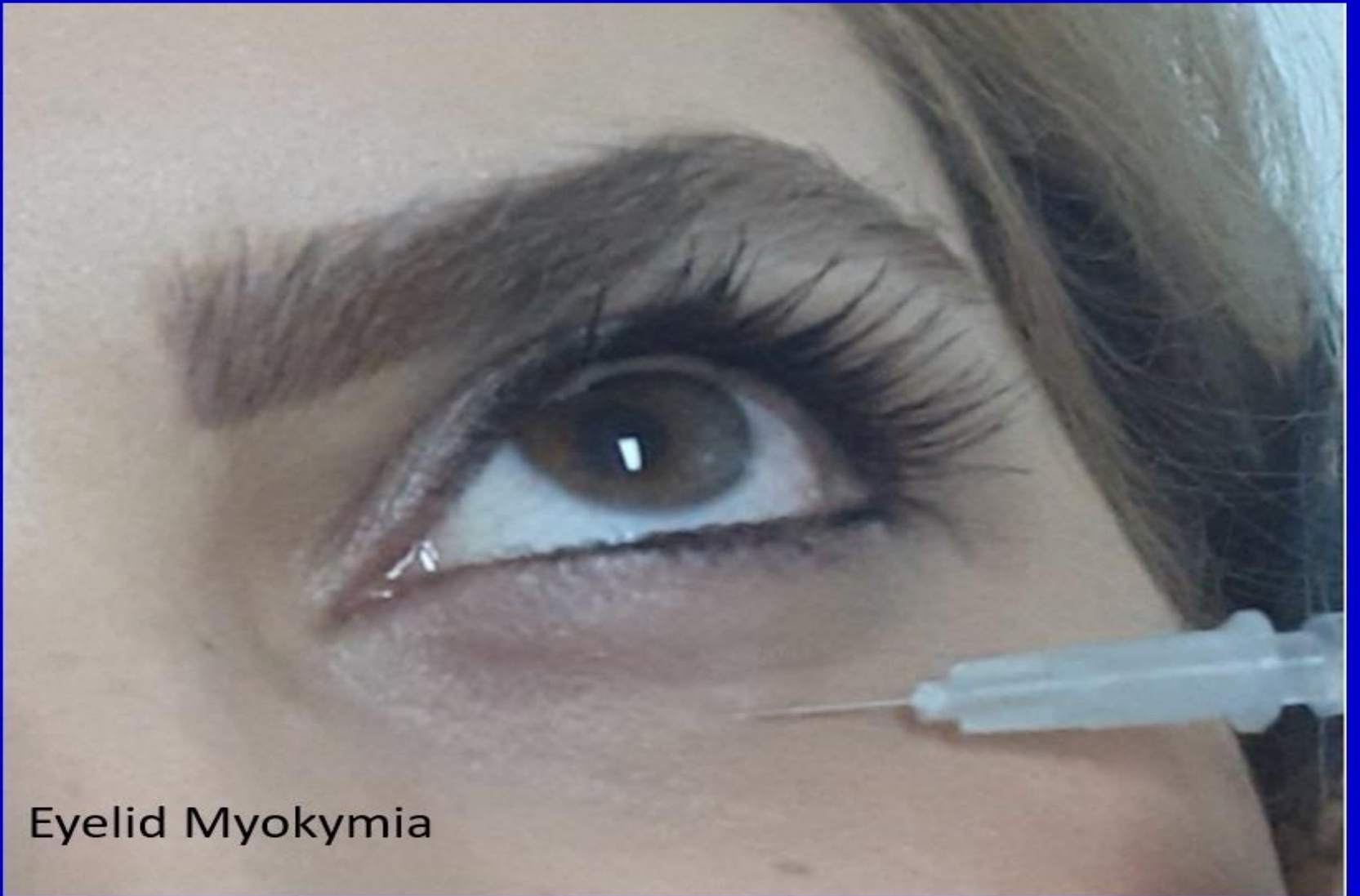Dr Naser Karimi, MD



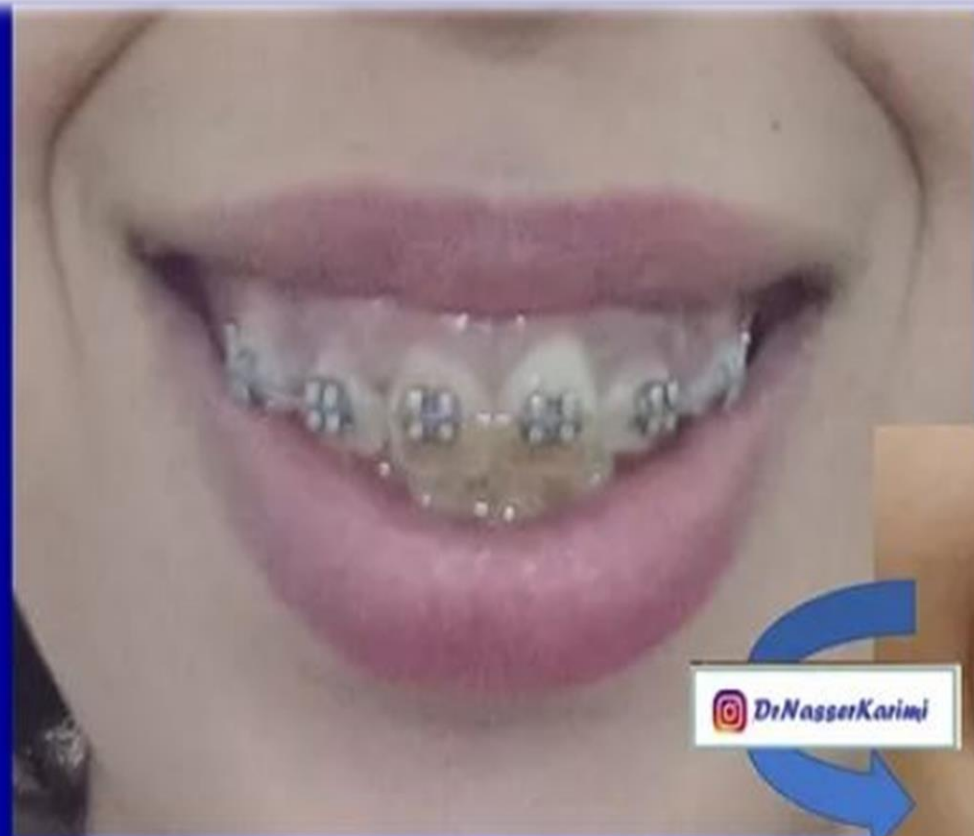

 **DrNasserKarimi**

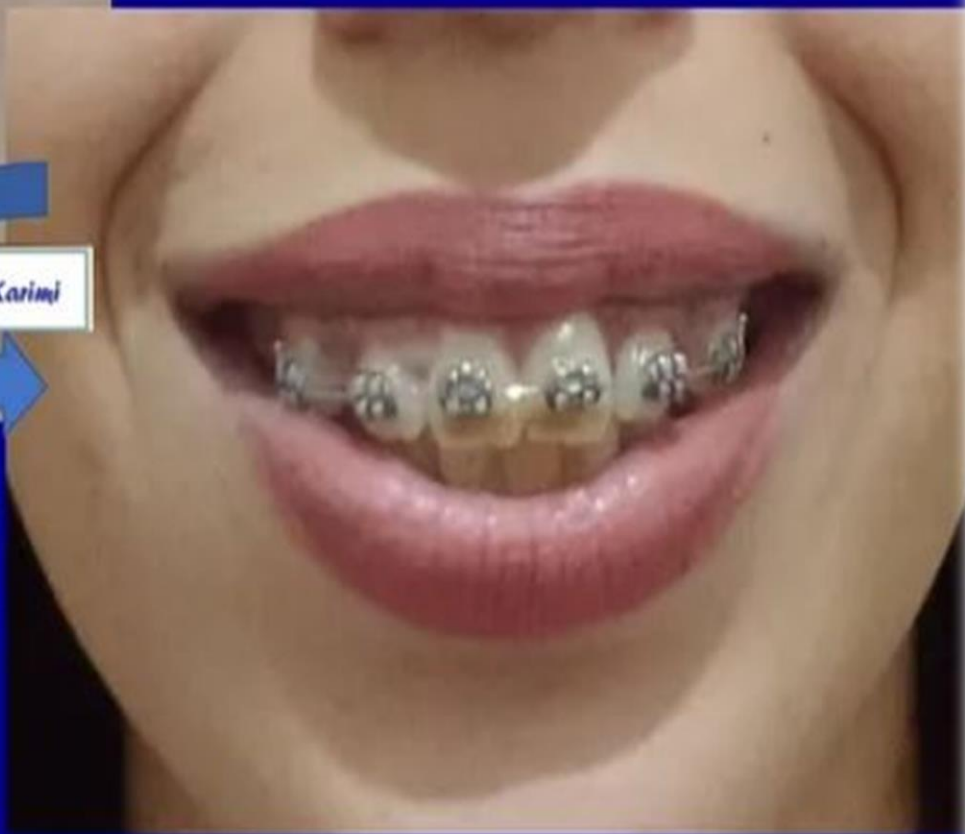


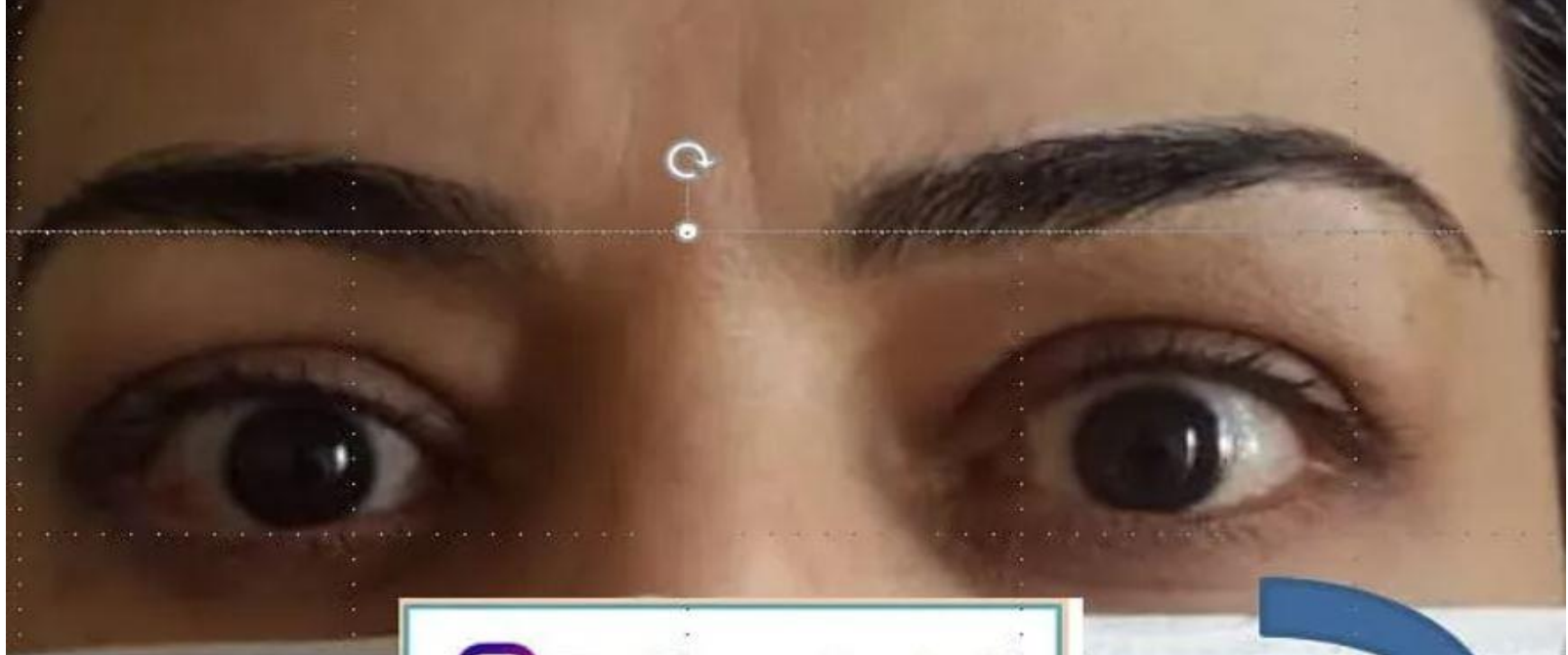


Eyelid Myokymia

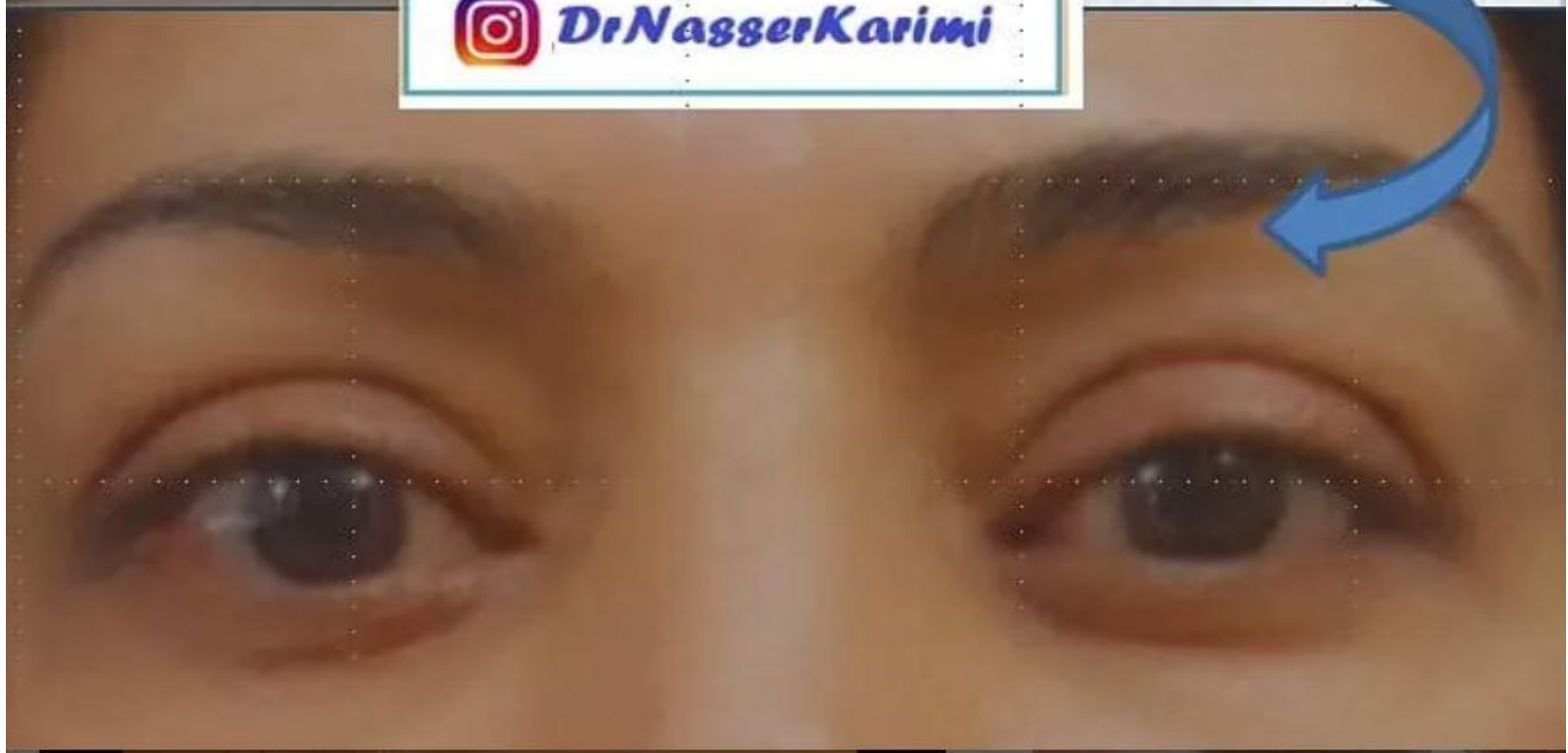

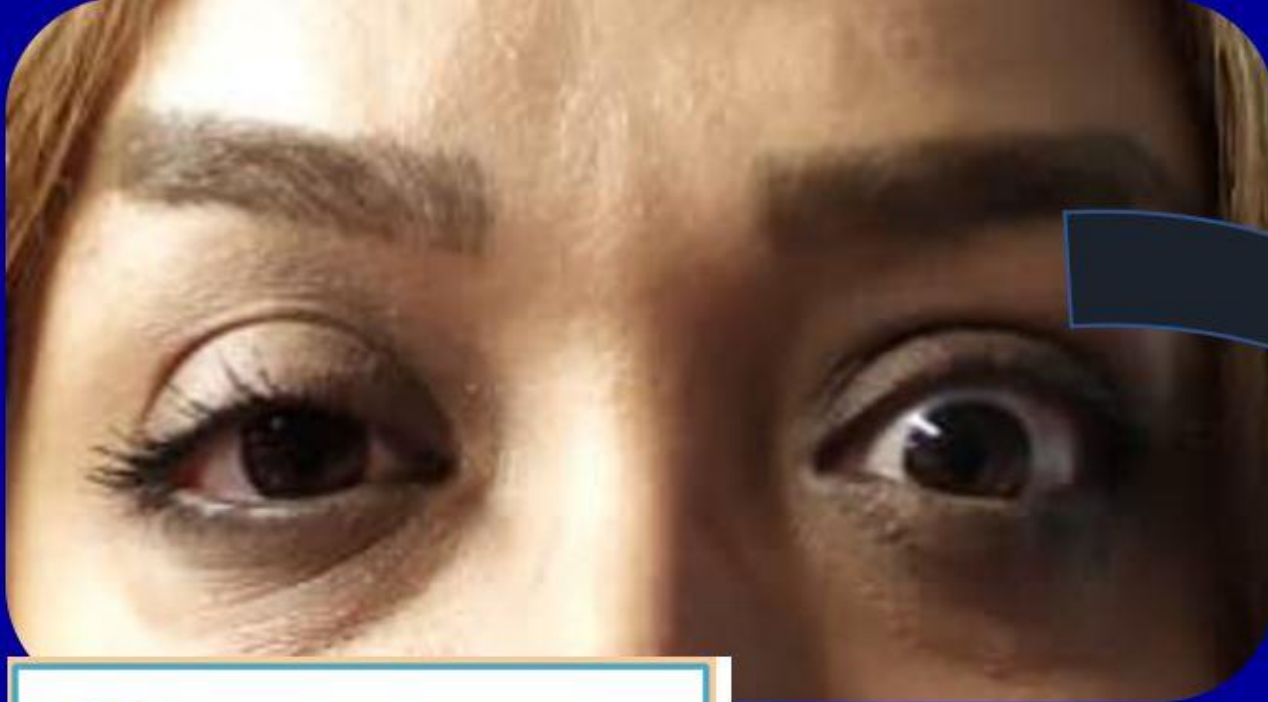 *DrNasserKarimi*





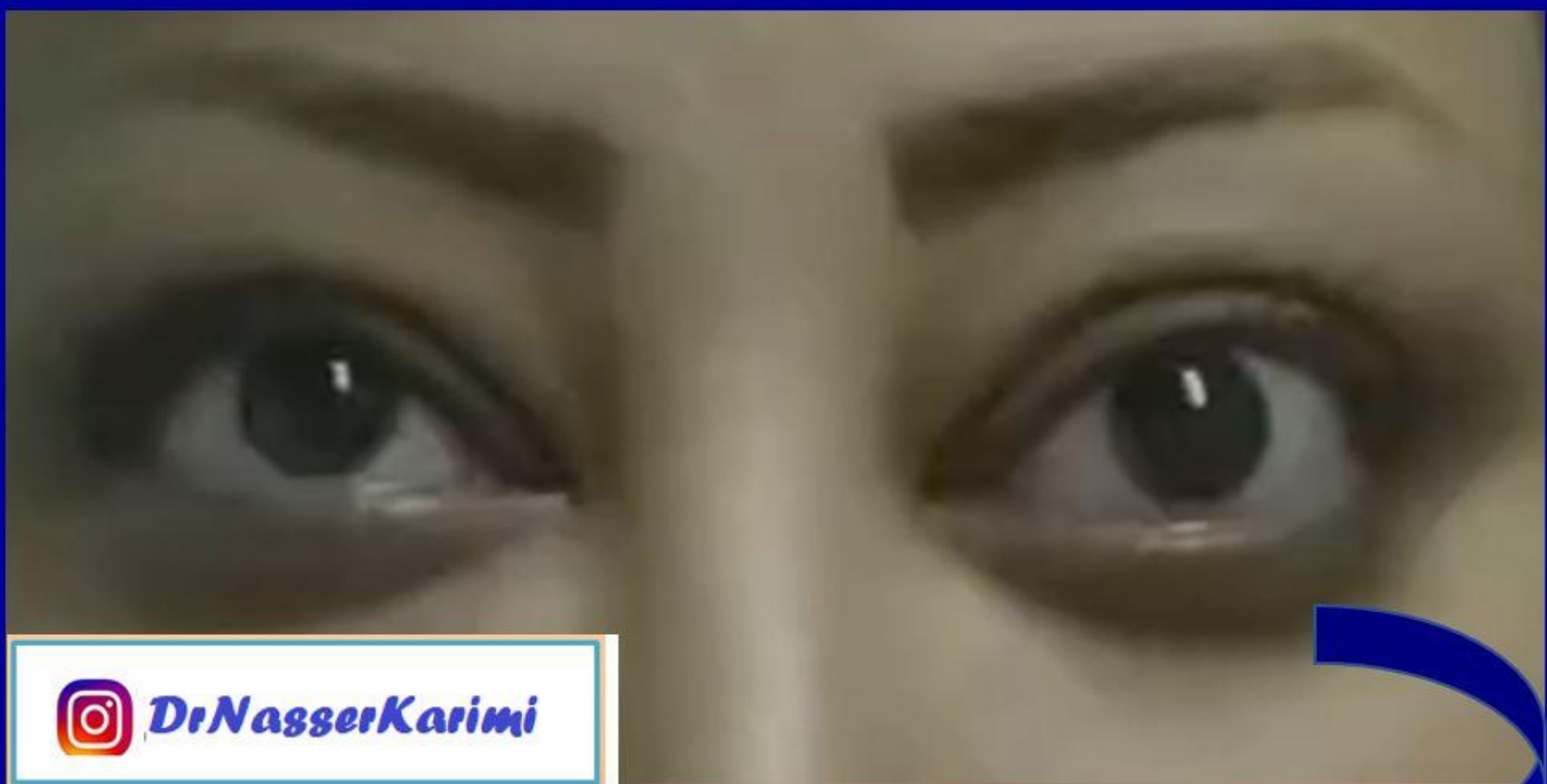 *DrNasserKarimi*



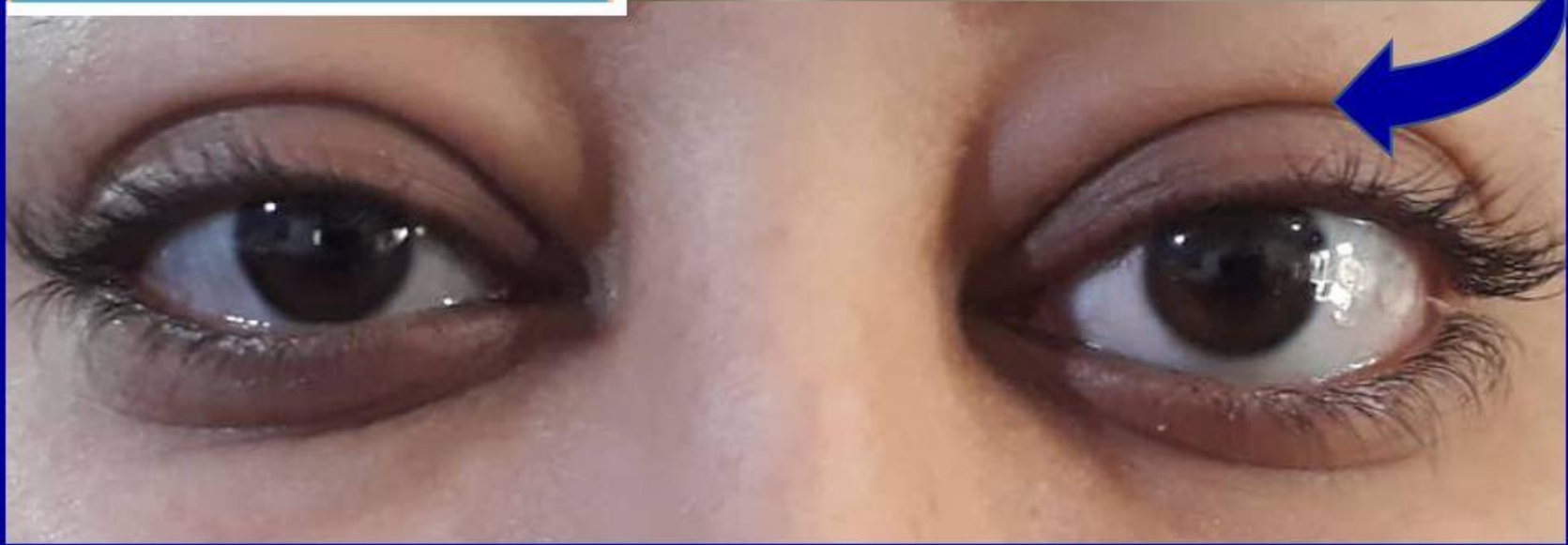

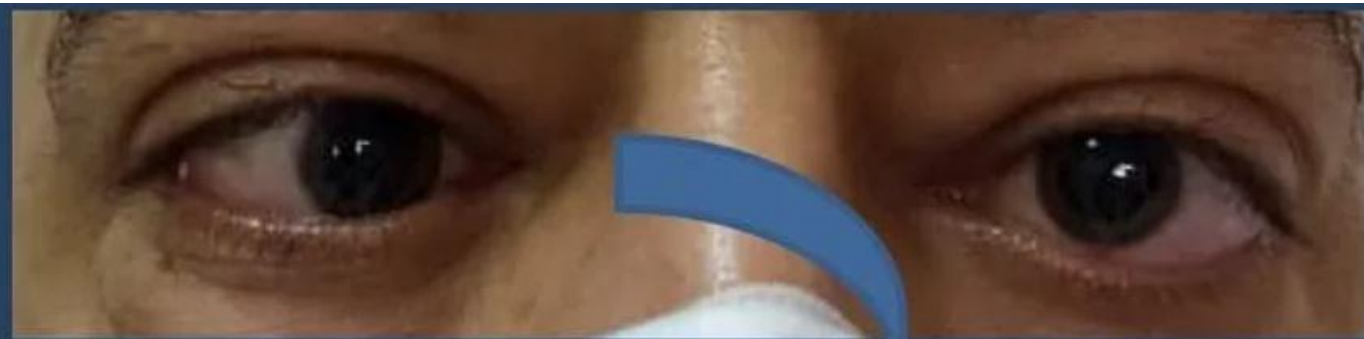DrNasserKarimi



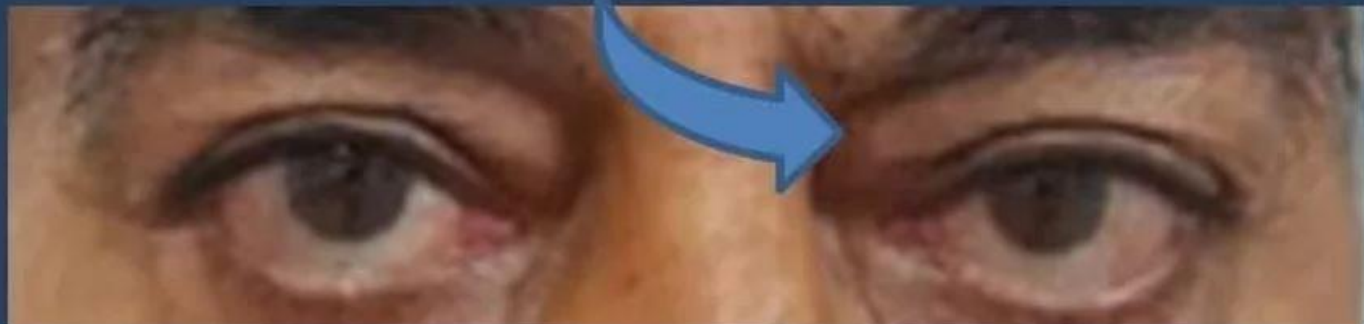

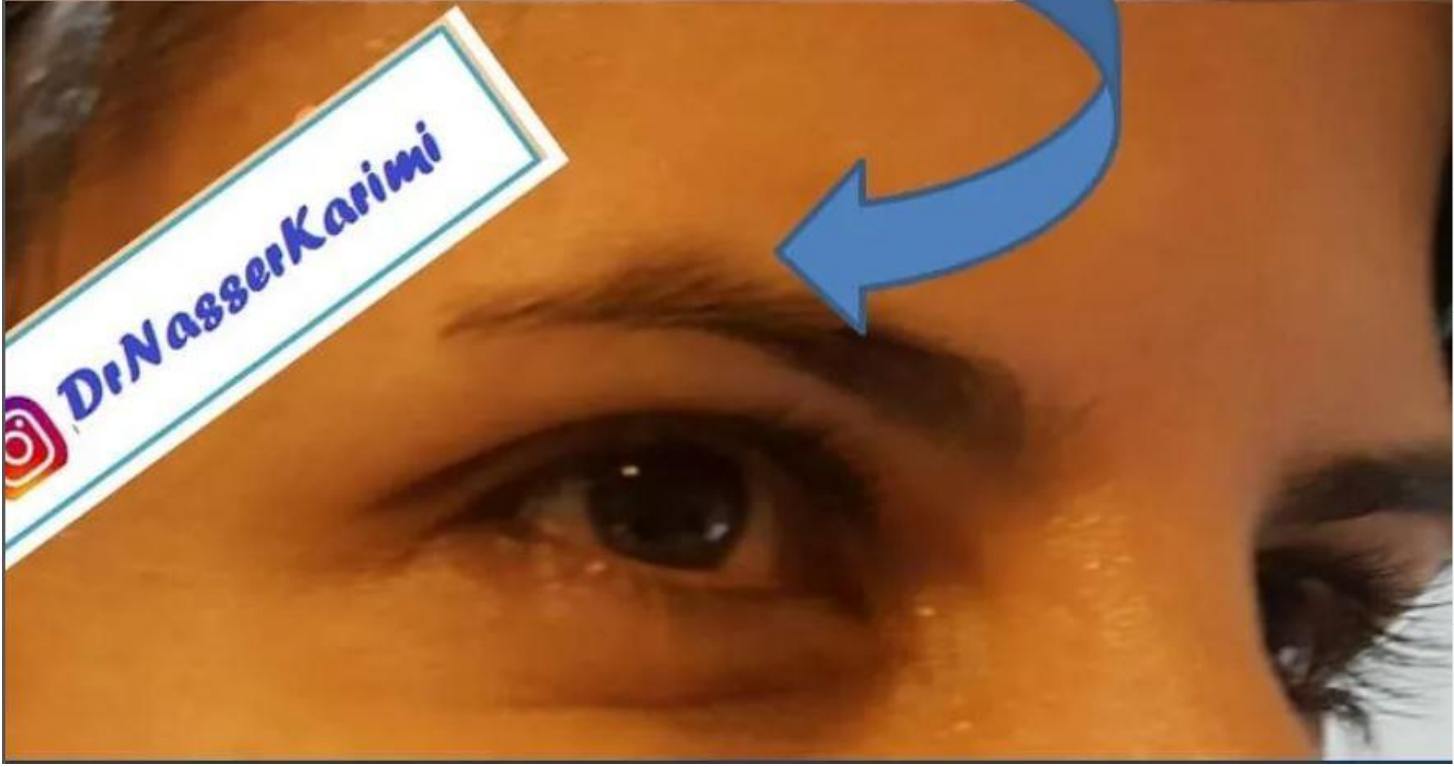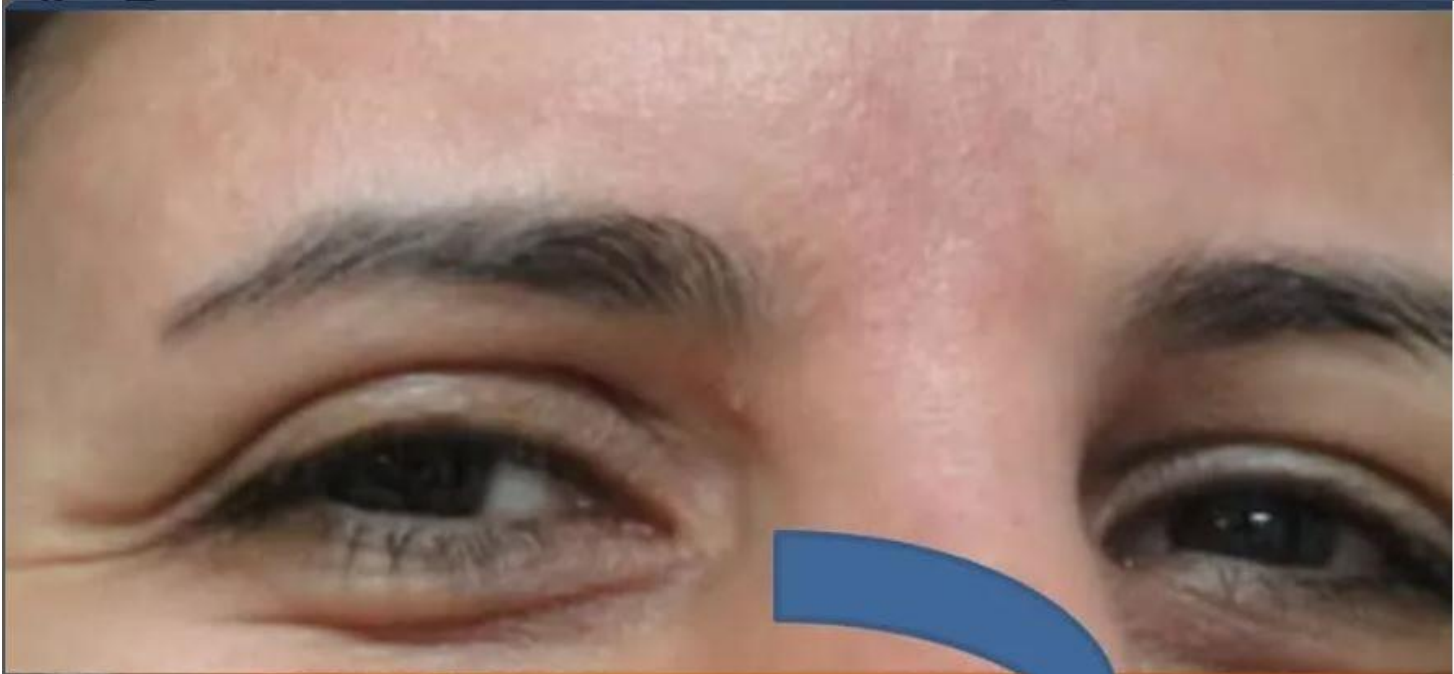 **DrNasserKarimi**





 ***DrNasserKarimi***



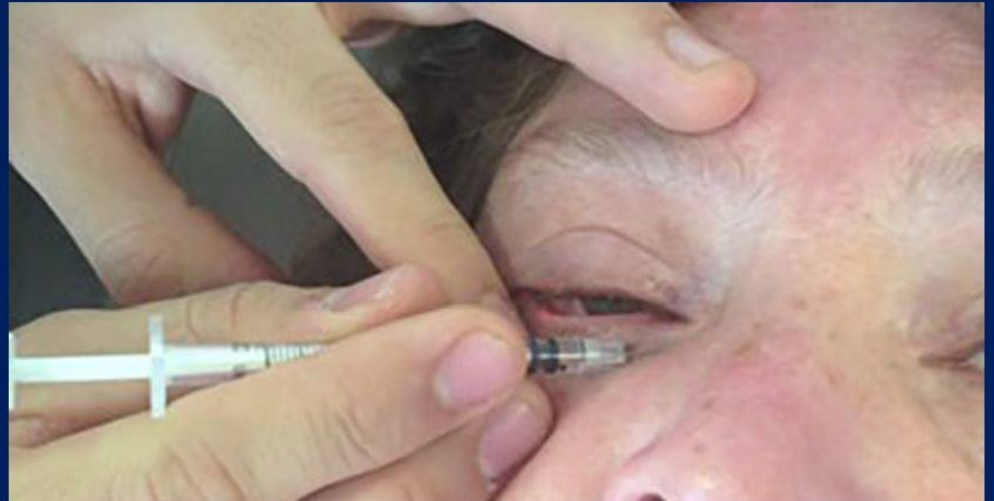

BTA: increasing tear retention Dry Eye Syndrome

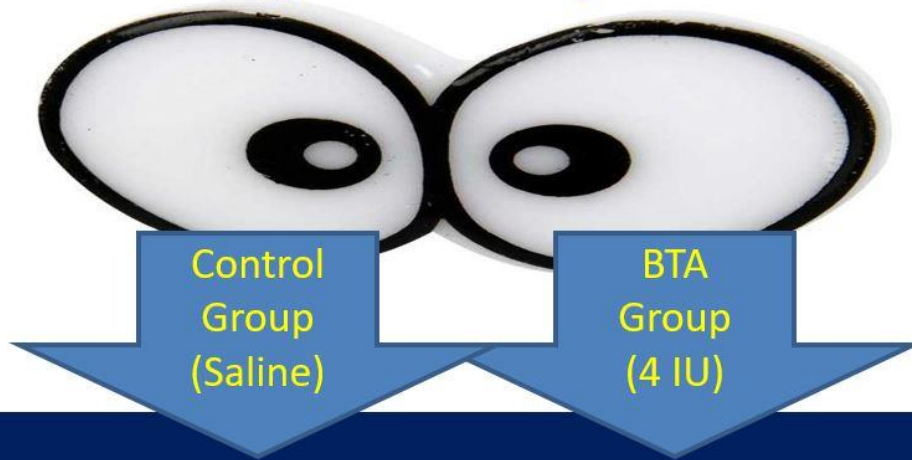
Subcutaneous

Near the punctum

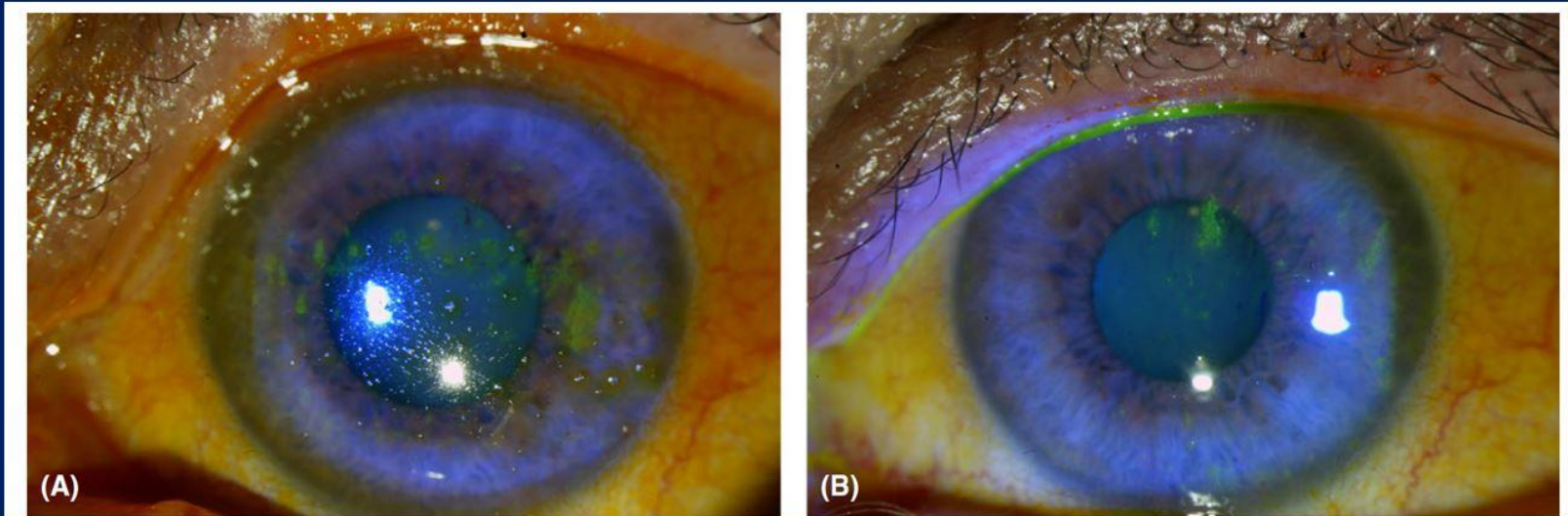
Directed along the medial canthal tendon



40 eyes of 20 patients



Better symptom scores 4 weeks after the treatment,
Corneal and Conjunctival staining were significantly lower
Schirmer's test showed better measurements



Pearls and Pitfalls in Therapeutic Injection of Botox

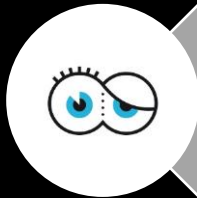
By: Behzad Khademi M.D.

Ophthalmic Plastic and Reconstructive surgeon

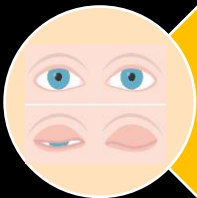
Shiraz University of Medical Sciences



Symmetry and cosmesis




Ptosis



Lagophthalmos


Symmetry in HFS



Mild facial palsy



Excessive muscle dynamics



Symmetry in HFS

- Facial asymmetry is caused by:
 1. BT-induced mild facial weakness of the primary affected facial muscles
 2. Wider palpebral fissures
 3. Higher eyebrows
 4. Shallower wrinkles
 5. Downward curving mouth corners
- It is usually brought out by mimetic muscle activation

Facial asymmetry can also be induced after BoNT-A treatment, with an incidence ranging from 6.9 to 19.8 % because of facial weakness

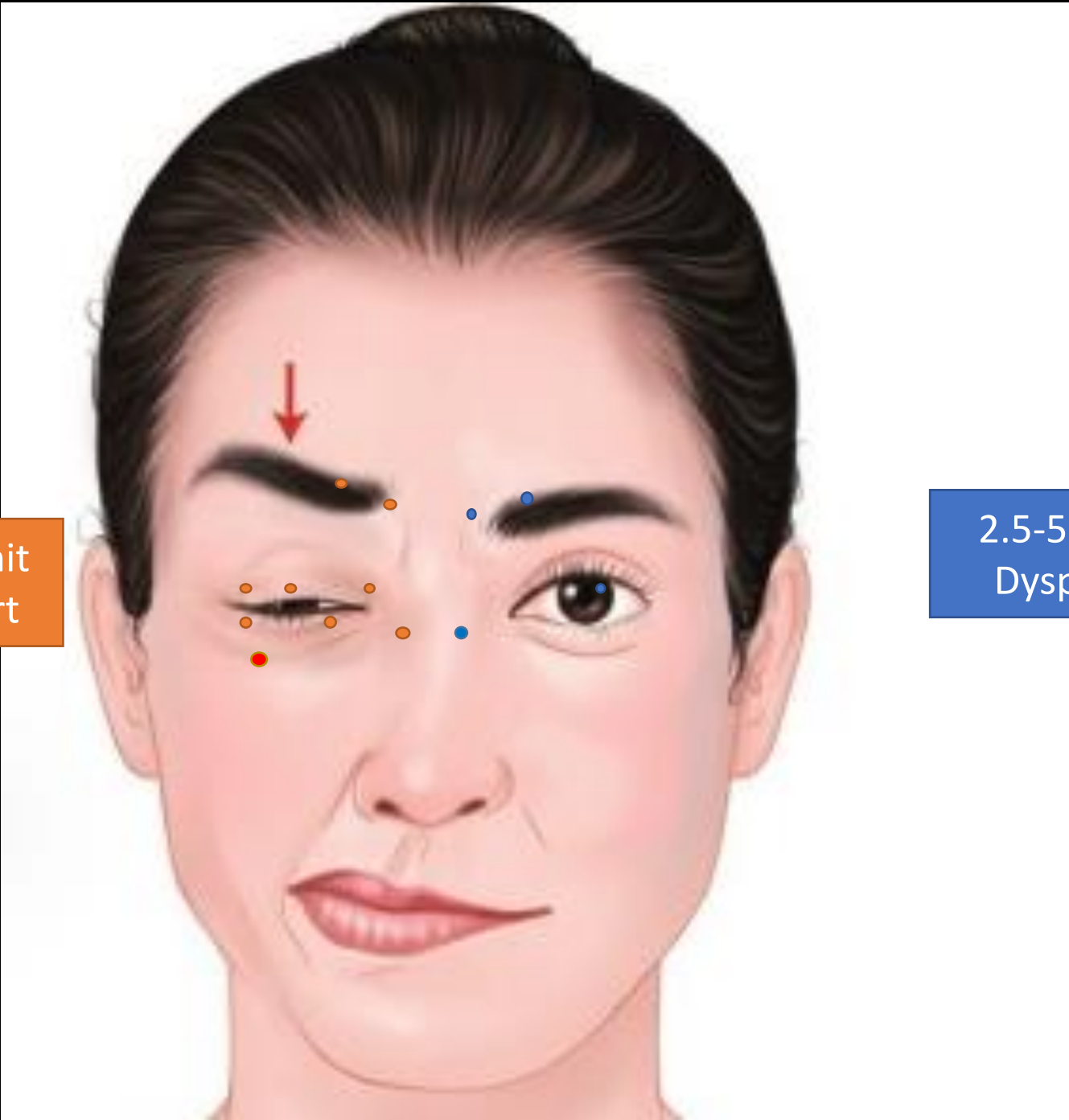
**Non-affected
mimic muscles**

The diagram consists of two yellow arrows pointing in opposite directions, one to the left and one to the right, connected by a central ribbon-like bridge. The left arrow contains the text 'Non-affected mimic muscles' in red, and the right arrow contains the text 'Bilateral BTA therapy' in blue. The background is black.

**Bilateral BTA
therapy**

Periocular injections

- Orbicularis oculi (4-6 points)
- Zygomaticus major/minor (1-2 point)
- Glabella (1-2 point)
- Nasalis (1point)



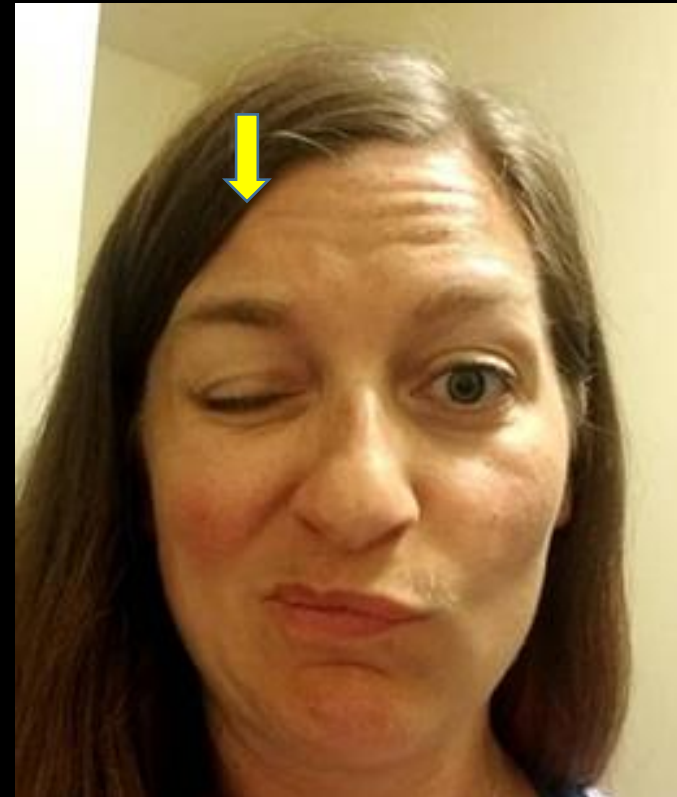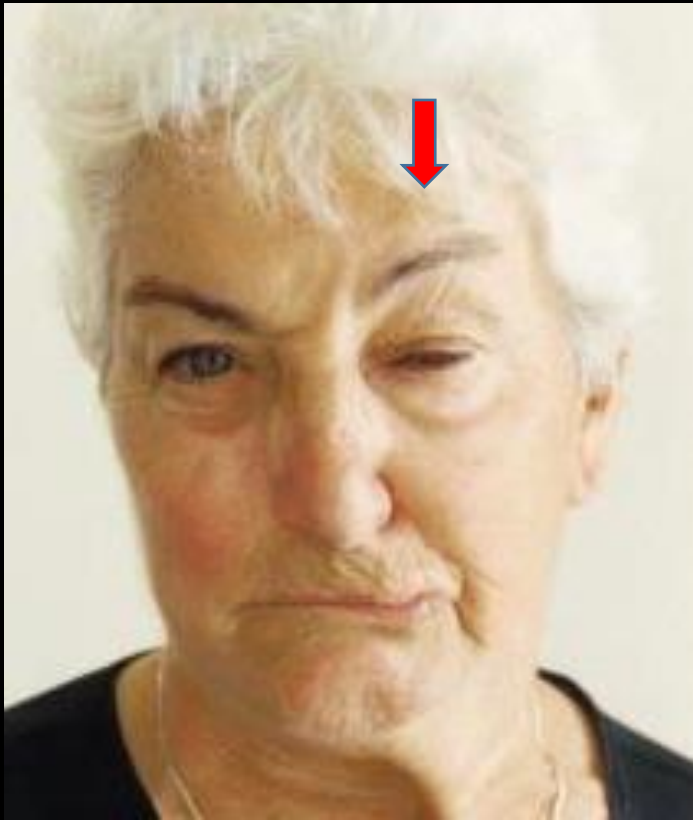5-10 unit
Dysport

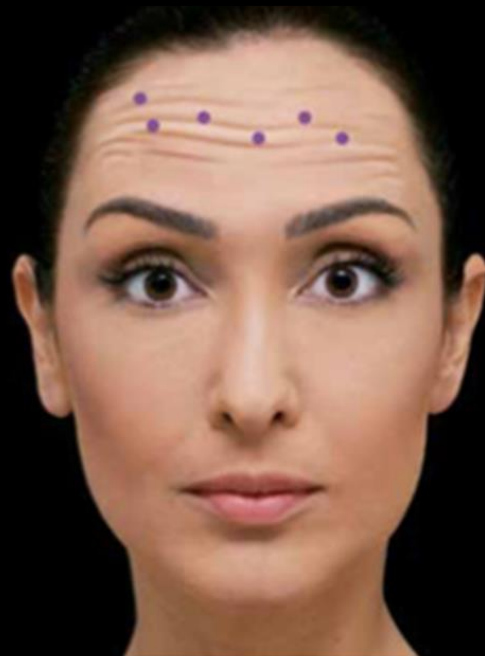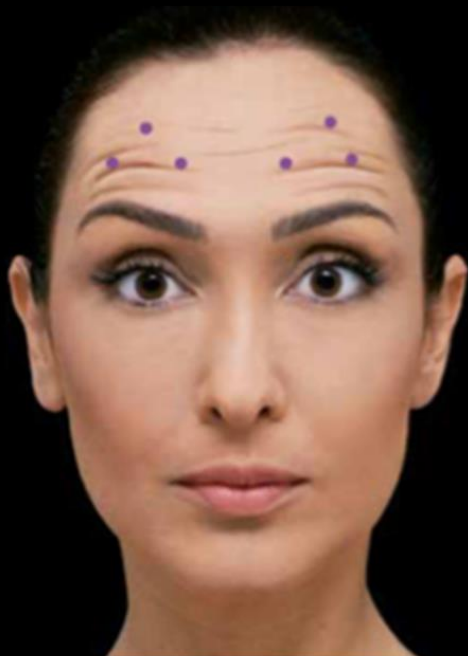2.5-5 unit
Dysport

- Regular BT doses on the affected side and **one-third** of these doses on the **non-affected side**
- Improves facial asymmetry at rest and during voluntary facial movements

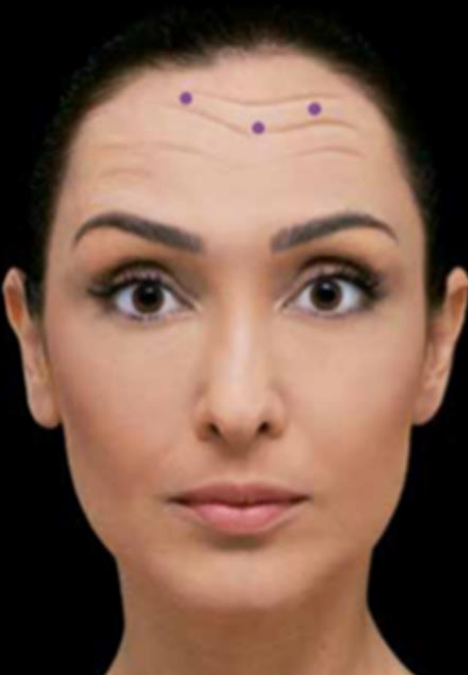Frontalis injections

Pay attention to the patterns of frontal lines

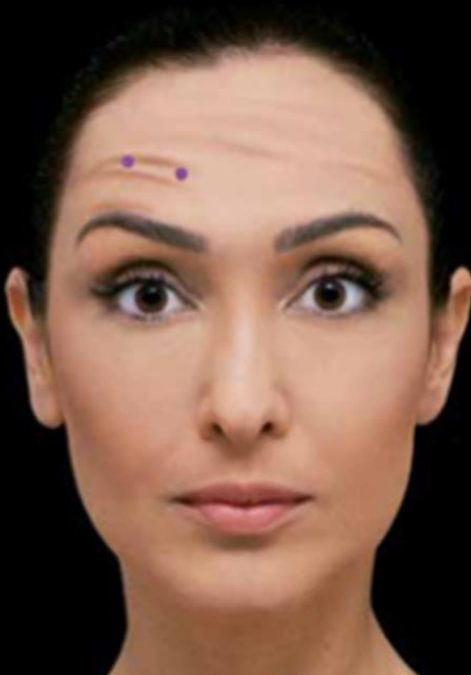



E

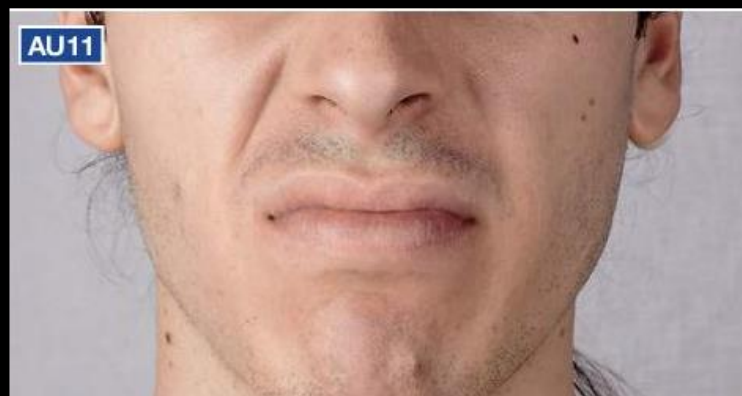
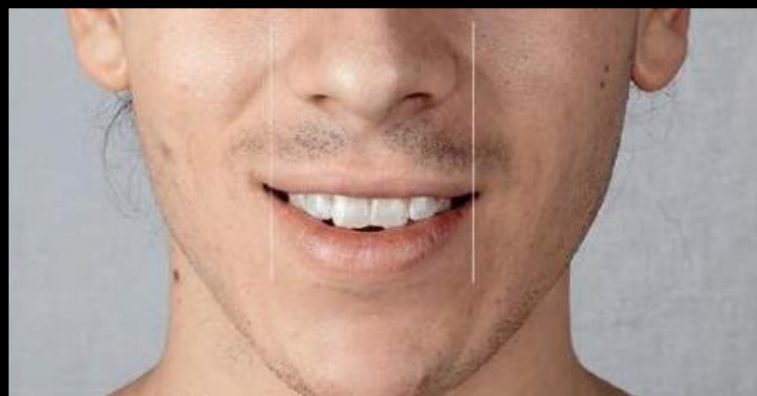
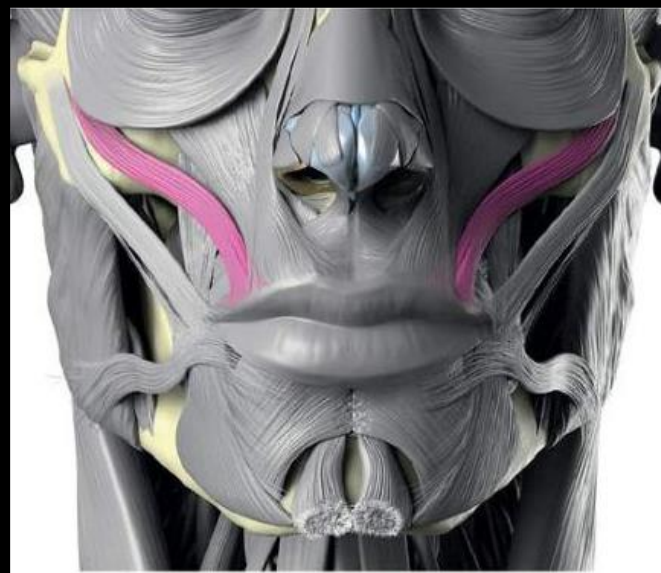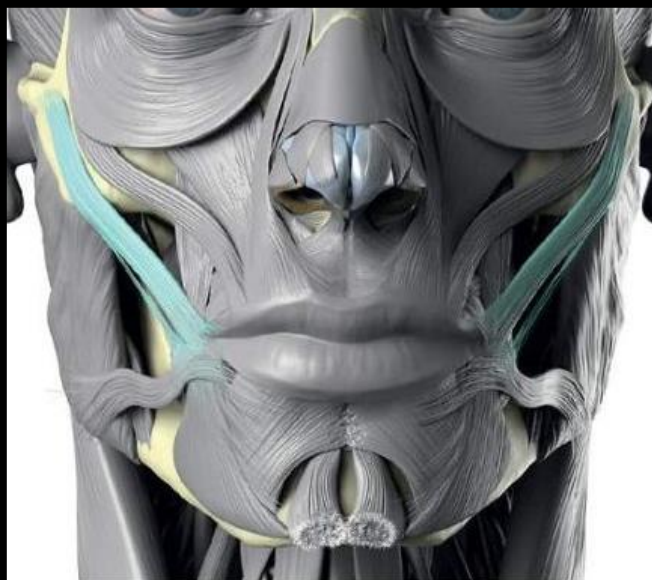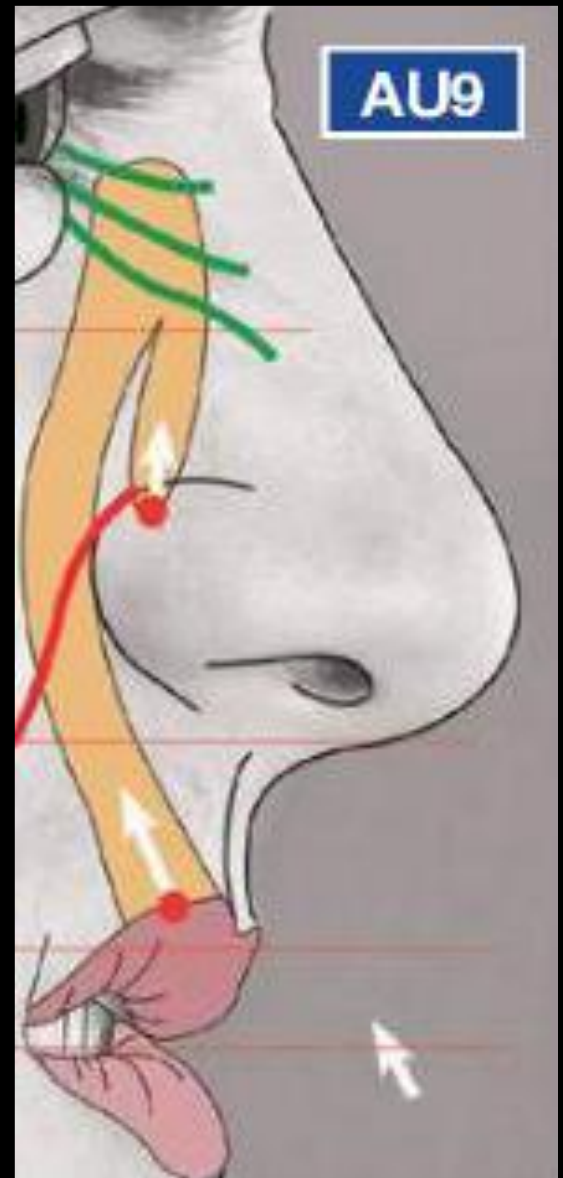
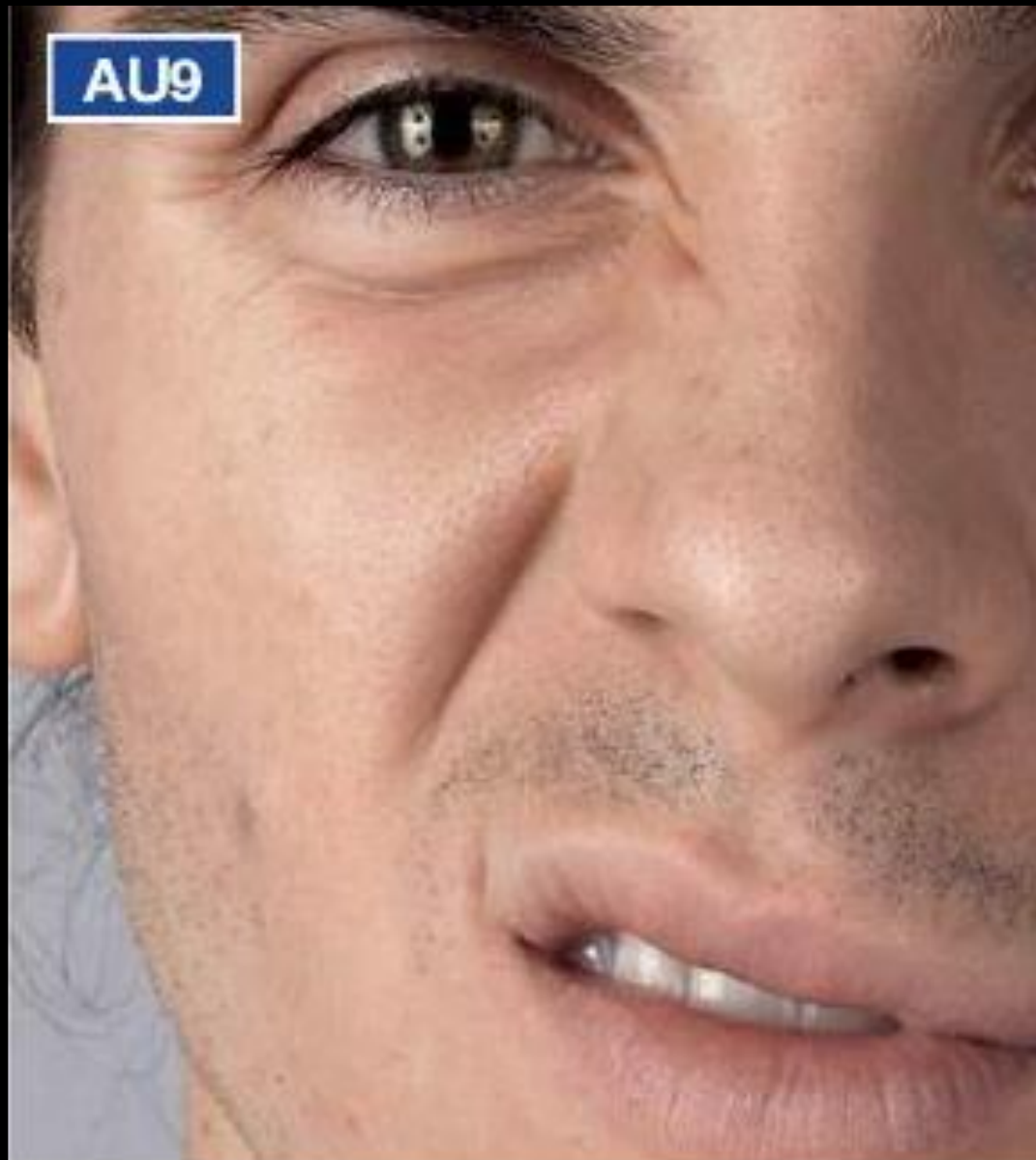F



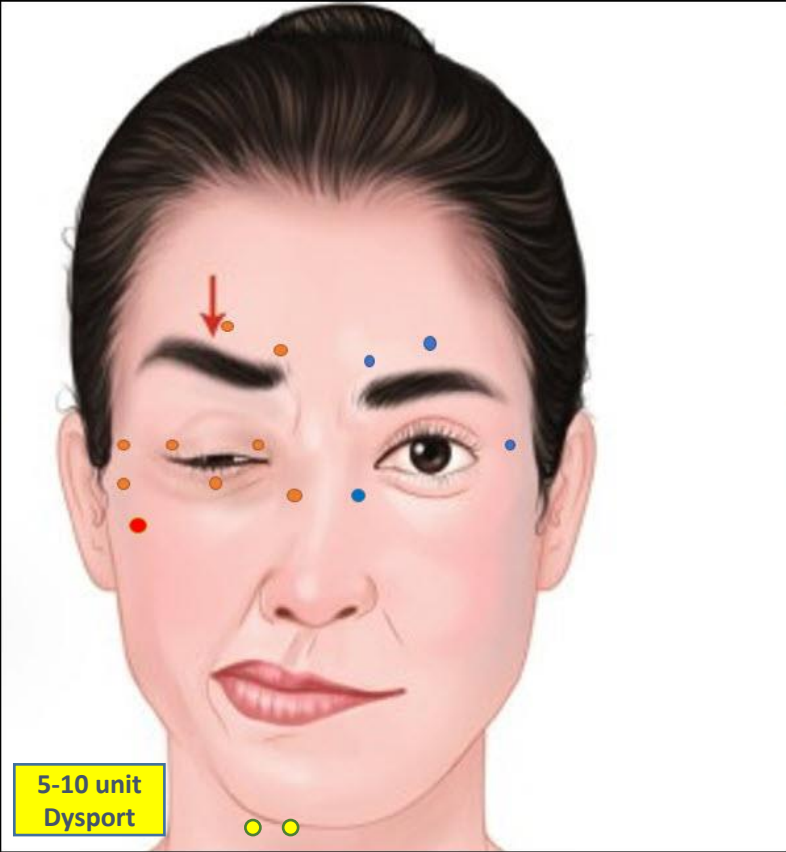
- It is recommended to inject **lower-than-normal amounts** at the initial treatment session
 - Two-week follow-up for possible additional injections
- After several sessions, a **customized dose and points** of injection scheme can be developed

- The mid and lower face are the most challenging areas to be treated
- Over-injection of the muscles can result in:
 - Paralyzed appearance
 - Oral incompetence
- Lip asymmetry and lip ptosis are seen if:
 1. Toxin is injected below upper margin of zygomatic arch
 2. Along lower portion of nasal sidewalls



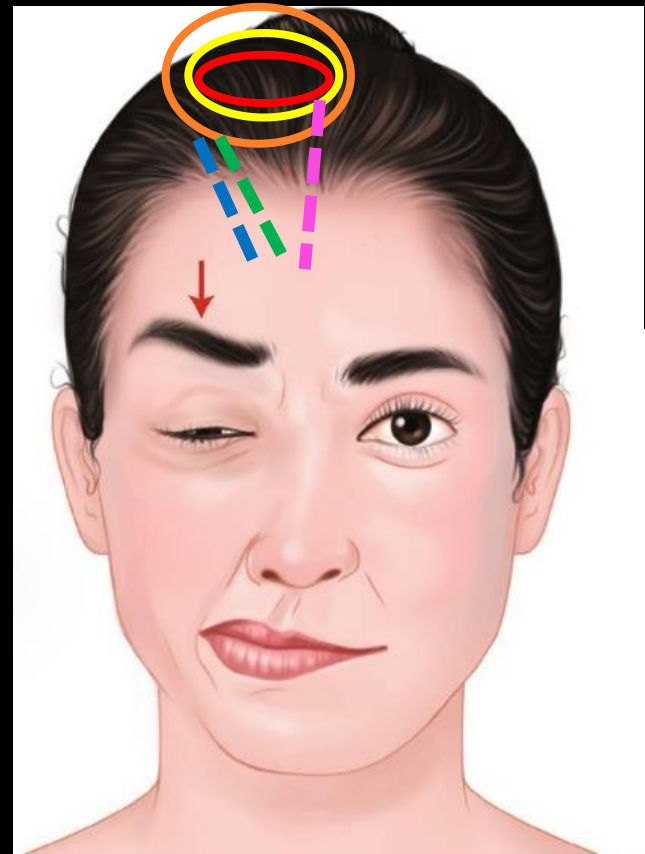


5-10 unit
Dysport

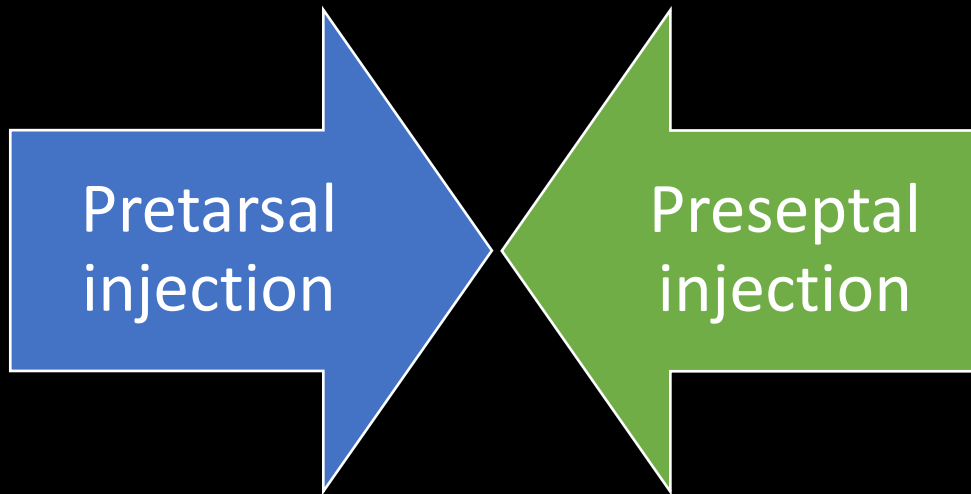


2.5-5 unit
Dysport

5-10 unit
Dysport



Lagophthalmos





AMERICAN ACADEMY
OF OPHTHALMOLOGY®

Ophthalmic Technology Assessment

Chemodenervation for the Treatment of Facial Dystonia

A Report by the American Academy of Ophthalmology

Jurij R. Bilyk, MD,¹ Michael T. Yen, MD,² Elizabeth A. Bradley, MD,³ Edward J. Wladis MD,⁴
Louise A. Mawn, MD⁵

- Pretarsal injections of Botox are more effective than preseptal injections

**Complications of Preseptal Versus Pretarsal
Botulinum Toxin Injection in Benign Essential
Blepharospasm: A Randomized Controlled Trial
2021 AJO**

- Higher rate of self-reported lagophthalmos in Pretarsal than Preseptal
- Higher measured lagophthalmos in Pretarsal than in Preseptal
- No significant difference in the efficacy and other complication outcomes between the injection locations was observed

Ptosis

- This issue is area of concern in injection of BTA for treatment eyelid retraction and treatment of lacrimation
- Ptosis, probably the most common and debilitating side effect, being present in 3.2–18%
- Injection of the **pretarsal** segment of the upper eyelid, **just onto or even lateral** to the conjunction of the upper and lower eyelids, lowers the risk of ptosis

Diplopia

- Diplopia, an occasionally encountered and debilitating side effect, occurring in up to 5%
- Keep at least 1cm distance from lateral orbital rim
- Strict avoidance of injection medial to pupil in the lower eyelid
 - Prevent diffusion of the toxin into the inferior oblique or the inferior rectus

Regular BT doses on the affected side and **one-third** of these doses on the **non-affected side**

Pay attention to the patterns of frontal lines

Be judicious for lower face injection

Inject preseptal orbicularis in lower eyelid

Do not inject medially in the lower lid, which might cause diplopia or epiphora

Inject **lower-than-normal amounts** at the initial treatment session

Customized dose and points of injection

